



Autoimmune encephalitis associated with autoimmune blistering diseases: A case series and retrospective review

Andrew R Tadros, *Emory University*

George Atteh, *Emory University*

Diana L Vargas, *Emory University*

Emily Cole, *Emory University*

[Ron Feldman](#), *Emory University*

Journal Title: JAAD Case Reports

Volume: Volume 37

Publisher: Elsevier, Inc. | 2023-07-01, Pages 92-97

Type of Work: Article | Final Publisher PDF

Publisher DOI: 10.1016/j.jdc.2023.04.030

Permanent URL: <https://pid.emory.edu/ark:/25593/w7hj4>

Final published version: <http://dx.doi.org/10.1016/j.jdc.2023.04.030>

Copyright information:

© 2023 by the American Academy of Dermatology, Inc. Published by Elsevier, Inc.

This is an Open Access work distributed under the terms of the Creative Commons Attribution-NonCommercial-NoDerivatives 4.0 International License (<https://creativecommons.org/licenses/by-nc-nd/4.0/>).

Accessed April 20, 2024 6:36 PM EDT

Autoimmune encephalitis associated with autoimmune blistering diseases: A case series and retrospective review



Andrew R. Tadros, MD, PhD,^a George Atteh, MD,^a Diana L. Vargas, MD,^b Emily F. Cole, MD, MPH,^a and Ron J. Feldman, MD, PhD^a

Key words: autoimmune blistering skin disease; autoimmune encephalitis; case series; dermatology; retrospective review.

INTRODUCTION

Autoimmune blistering skin diseases (AIBDs) comprise a group of immune-mediated disorders characterized by the presence of autoantibodies directed against cutaneous epitopes resulting in frequent blister formation. Associations between the most common AIBDs, pemphigus, and pemphigoid and other inflammatory or autoimmune diseases have been described, so-called autoimmune diathesis.¹ This diathesis has been well described with regard to pemphigoid and concomitant neurologic inflammatory or autoimmune diseases such as Alzheimer' disease, Parkinson' disease, and multiple sclerosis.^{2,3} These neurocutaneous associations are hypothesized to be, at least in part, caused by autoantibodies directed at both cutaneous and neurologic tissues. Due to their shared embryologic origin, several receptor binding domains are co-expressed across both dermatologic and neurologic tissues (eg, BP180, BP230). Cross-reactive antibodies are believed to play a role in mediating the clinical sequelae related to the skin; although the role in various neurological diseases is still unclear, with circulating anti-BP180, 230 autoantibodies reported in patients with Alzheimer disease and Parkinson disease.^{4,5}

Autoimmune encephalitis (AE) encompasses a group of diseases characterized by autoantibodies targeting various epitopes of the central nervous

Abbreviations used:

AE:	autoimmune encephalitis
AIBD:	autoimmune blistering skin disease
BCC:	basal cell carcinoma
CASPR2:	anti-contactin-associated protein-like 2
CI:	confidence interval
CSF:	cerebrospinal fluid
CVA:	cerebrovascular accident
DIF:	direct immunofluorescence
Dx:	diagnosis
ELISA:	enzyme linked immunosorbent assay
ISD:	inflammatory skin disease
IVIG:	intravenous immunoglobulin
MMF:	mycophenolate
MMP:	mucous membrane pemphigoid
MS:	multiple sclerosis
NMSC:	nonmelanoma skin cancer
OCP:	ocular cicatricial pemphigoid
PLEX:	plasma exchange
RRR:	relative risk ratio
SCC:	squamous cell carcinoma
SD:	standard deviation

system.⁶ Patients with AE often experience neuropsychiatric symptoms, leading to significant medical morbidity. An autoimmune diathesis has also been reported in patients with AE, including concurrent Hashimoto's thyroiditis and systemic lupus erythematosus.⁷ Interestingly, some studies have shown cutaneous findings prior to the diagnosis of antibody-positive autoimmune encephalitis further suggesting an association with dermatologic

From the Department of Dermatology, Emory University School of Medicine, Atlanta, Georgia^a; and Department of Neurology, Emory University School of Medicine, Atlanta, Georgia.^b

Funding sources: None.

IRB approval status: Approved (IRB00114505).

Patient consent: Consent for the publication of all patient photographs and medical information was provided by the authors at the time of article submission to the journal stating that all patients gave consent for their photographs and medical information to be published in print and online and with the understanding that this information may be publicly available.

Correspondence to: Ron J. Feldman, MD, PhD, Department of Dermatology, Emory University, 1525 Clifton Rd, Suite 100, Atlanta, GA 30322. E-mail: ron.j.feldman@emory.edu.

JAAD Case Reports 2023;37:92-7.

2352-5126

© 2023 by the American Academy of Dermatology, Inc. Published by Elsevier, Inc. This is an open access article under the CC BY-NC-ND license (<http://creativecommons.org/licenses/by-nc-nd/4.0/>).

<https://doi.org/10.1016/j.jidcr.2023.04.030>

Table I. A retrospective review was conducted within a 20-year period based on ICD codes for dermatologic disease and AE

Indication	ICD9	ICD10
Autoimmune encephalitis	323.9, 323.81	G.04.9, G04.81
Alopecia areata	704.01	L63.9
Atopic dermatitis	691.8	L20-L30
Psoriasis	696.1	L40.9
Pemphigus, pemphigoid, and other bullous skin diseases	694-694.9	L10-L14
Vitiligo	709.01	L80
Nonmelanoma skin cancer	173.0-173.9	C44

ICD codes identified for patients with AE, alopecia areata, atopic dermatitis, psoriasis, pemphigus, pemphigoid and other bullous disorders, vitiligo, and NMSC.

diseases.⁸ In this report, we highlight 3 cases of patients with AIBD who subsequently developed AE. We also further broadened this search to explore a potential association of inflammatory and autoimmune skin diseases with AE.

METHODS

For the case series, clinical data were collected from all 3 patients seen by the same dermatologist and diagnosed based on confirmative clinical, histological, and serological criteria. All 3 cases were co-managed with a neuroimmunologist who confirmed the diagnosis of AE.

A 20-year retrospective review of patients in the Emory Healthcare System with autoimmune or inflammatory skin diseases (alopecia areata, AIBD, psoriasis, atopic dermatitis, and vitiligo) and AE was conducted following approval by the institutional review board of Emory University (IRB00114505). Confirmation of a dermatologic diagnosis for AIBD, psoriasis, atopic dermatitis, vitiligo, alopecia areata, vitiligo, or nonmelanoma skin cancer (NMSC) was based on a combination of clinical, laboratory, and pathologic data. Clinical diagnosis was based on several factors including presentation (eg, symptoms, visual appearance/description of skin morphology, and response to therapy). Supporting laboratory information included pathologic confirmation as assessed and recorded within the electronic health record. Confirmation of NMSC was assessed by pathologic confirmation and response to excisional therapy. Diagnosis was recorded as the date in which an International Classification of Diseases (ICD) code was first used to identify the skin disease (Table I).

To identify patients within the full database query with confirmed or probable AE, we utilized clinical standards for diagnosis of AE. Patients must have satisfied the following 3 criteria for inclusion as confirmed AE: (1) subacute onset of neuropsychiatric symptoms (less than 3 months), (2) at least 1 of the

following: new focal central nervous system findings, seizures not explained by a seizure disorder, CSF pleocytosis (white blood cell count >5 cells/mm³), or magnetic resonance imaging suggestive of encephalitis, and (3) a reasonable exclusion of alternative causes (eg, infectious, trauma, neoplasm, toxic/metabolic).⁹ To further interrogate the patients we manually identified, all cases of interest were reviewed by a neurologist to adjudicate the final diagnosis, according to information available within the electronic health record. Date of diagnosis was recorded as the first date the ICD code diagnosis appeared within the electronic health record. Patients who were identified through the database query were manually reviewed for clinical symptoms and temporal pattern of disease onset, and CSF analysis from lumbar puncture. If no CSF findings were found, a diagnosis of exclusion was utilized to assess for probable AE. The diagnosis of exclusion includes the above listed 3 criteria with the modification of having at least 2 of the following 3 criteria: (1) MRI findings suggestive of AE, (2) CSF pleocytosis, CSF-specific oligoclonal bands or elevated CSF IgG index, or both, or (3) brain biopsy confirming inflammatory infiltrates and excluding other disorders.⁹

RESULTS

Herein, we summarize the clinical characteristics of 3 patients with concurrent AIBD and AE (Table II). All patients developed AIBD prior to AE with AIBD diagnoses including pemphigus vulgaris and mucous membrane pemphigoid. The patient with PV developed anti-LGI1 encephalitis while the MMP patients developed clinical manifestations of AE absent detectable autoantibodies. The mean age was 70 ± 8.8 years and AE developed mean 13.3 ± 5.0 months after a diagnosis of AIBD. Two of the patients had previously received rituximab therapy for AIBD when they developed AE. All 3 patients presented with subacute onset of confusion with 2 patients having tremors and muscle spasms,

Table II. Patients identified in case series with AIBD and subsequent development of AE

Patient initials	Patient 1	Patient 2	Patient 3
Age	65	65	80
Gender	Male	Female	Female
Race	White	White	White
Type of AIBD	Pemphigus vulgaris	OCP	MMP
Diagnosis of AIBD	Clinical + ELISA	Clinical + DIF	Clinical + DIF
Past medical history	Hashimoto thyroiditis	None noted	Bladder transitional cell carcinoma
Date of AIBD diagnosis	May-2018	Jan-2018	Oct-2018
Date of AE diagnosis	Nov-2019	Mar-2019	Jun-2019
Time between AIBD and AE diagnosis	18 mo	14 mo	8 mo
Presenting symptoms of AE	Confusion, migraine with visual aura, tremor, abdominal muscle spasms	Confusion, weakness, tremors, dizziness, weight loss	Confusion, memory loss, combative behavior
Treatment used for AIBD at the time of AE diagnosis	Rituximab, MMF, topicals	MMF, Rituximab	Dapsone, topicals
Rituximab treatment year	2015	2017	n/a
Treatment used for AE	IV steroids, IVIG	IV steroids, IVIG, PLEX	IVIG
Response to AE treatment	Moderate	Poor	Excellent
AE Antibody studies	Anti-LGI-1 positive	Negative	Negative

DIF, Direct immunofluorescence; ELISA, enzyme linked immunosorbent assay; IVIG, intravenous immunoglobulin; MMF, mycophenolate; MMP, mucous membrane pemphigoid; OCP, ocular cicatricial pemphigoid; PLEX, plasma exchange.

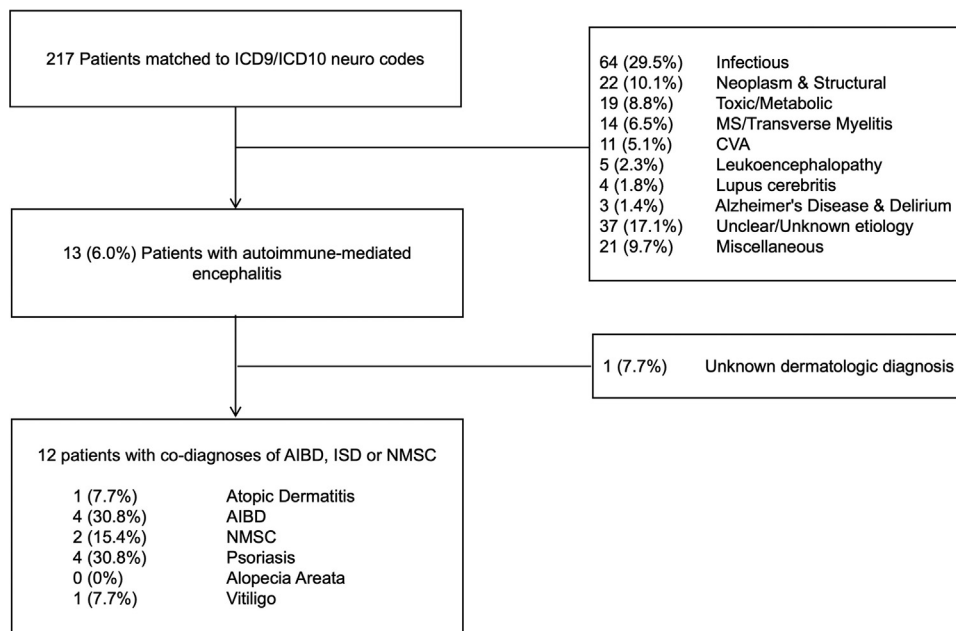


Fig 1. Flow diagram representing the retrospective review and assessment of patients identified based on ICD codes. 217 patients were identified based on ICD codes, however most patients within the full dataset had alternative neurologic diagnoses. 13 patients were identified with autoimmune-mediated encephalitis of which, 12 patients had confirmed inflammatory, autoimmune skin disease, or nonmelanoma skin cancer.

and 1 patient experiencing agitation. Patients were admitted for treatments including high dose intravenous steroids, intravenous immunoglobulin, and

plasma exchange with variable response as assessed clinically at the time of discharge per electronic medical record documentation.

Table III. Demographics of retrospective case series for patients with concurrent AE and dermatologic disease

Category	AE Confirmed (n = 12)
Sex, No. (%)	
Male	4 (33.3)
Female	8 (66.7)
Age of Neuro Dx, mean (SD) in years	52.4 (19.2)
Age of Derm Dx, mean (SD) in years	51.3 (18.7)
Race and ethnicity, No. (%)	
African American or Black	3 (25.0)
American Indian or Alaskan Native	0 (0.0)
Asian	0 (0.0)
Caucasian or White	7 (58.3)
Multiple	0 (0.0)
Native Hawaiian or other Pacific Islander	0 (0.0)
Not recorded	1 (8.3)
Unknown	1 (8.3)
Skin disorder prevalence, No. (%)	
Atopic dermatitis	1 (8.3)
Pemphigus/pemphigoid/other bullous dermatoses	4 (33.3)
BCC/SCC/other malignant neoplasm	2 (16.7)
Psoriasis	4 (33.3)
Alopecia Areata	0 (0.0)
Vitiligo	1 (8.3)
Neuro dx precedes derm dx, No. (%)	5 (41.7)
Time between neuro and derm dx, mean (SD) in months	26.8 (39.6)
Derm dx precedes neuro dx, No. (%)	7 (58.3)
Time between derm and neuro dx, mean (SD) in months	40.2 (20.4)

A search for patients with a co-diagnosis of NMSC and AE was performed as a control since there is no known association between the 2 conditions. Confirmation of AE diagnosis was made based on clinical standards. Dermatologic diseases were confirmed based on clinical, laboratory and histologic data.

Table IV. Summary table comparing patients identified with each dermatologic indication and those specifically with a codiagnosis of AE

Indication	Overall patient count over 20 years (n = 163,333)	Patient count in AE dataset over 20 years (n = 12)	20-year prevalence per 100,000 pts	RRR	95% CI
Atopic dermatitis	93,141	1	1.07	0.23	(0.02, 2.49)
Bullous disorders	7702	4	51.93	10.93	(2.00, 59.65)
NMSC	42,079	2	4.75	1.00	-
Psoriasis	15,586	4	25.66	5.40	(0.99, 29.48)
Vitiligo	2703	1	37.00	7.78	(0.71, 85.82)

The relative risk ratio (RRR) and 95% confidence intervals (CI) of each dermatologic indication is calculated relative to NMSC as a control group. The AE patient dataset was found to be statistically different from this overall patient dataset ($\chi^2 = 35.65, P < .0001$). There were no patients identified with alopecia areata within this retrospective search — data not shown.

Retrospective review of Emory Healthcare database for associated diagnoses based on ICD codes was completed (Fig 1). In total, 217 patients were identified, with 13 patients meeting criteria for codiagnosis of AE and a dermatologic diagnosis as summarized in Table III. Of the 13 patients with AE, 12 patients had confirmed skin disease (1 patient had an unknown dermatologic diagnosis). Most patients had dermatologic diagnosis preceding AE (8 vs 5).

The relative risk ratio (RRR) for each dermatologic indication was calculated and compared to patients with NMSC as a control (Table IV). Patients with AIBD had a significantly increased relative risk ratio (10.93, [2.00, 59.65]) compared to NMSC patients. Patients with psoriasis (5.40, [0.99, 29.48]) and vitiligo (7.78, [0.71, 85.82]) also had increased relative risk relative to NMSC but did not achieve statistical significance.

DISCUSSION

This study provides further support for increases in other autoantibody-mediated diseases in patients with AIBD. While our results did not reach significance with other inflammatory skin diseases, prior studies demonstrated anti-NMDAR and anti-LGI1 AE patients with concomitant inflammatory skin diseases (ISDs) such as vitiligo and chronic urticaria. In our cohort, most patients developed ISDs prior to the onset of AE, suggesting possible initial loss of tolerance to cutaneous epitopes. Genetic susceptibilities related to specific HLA class II alleles has been proposed in development of pemphigus and potentially shared in patients with anti-LGI1 encephalitis.¹⁰ Emerging data also suggest unique HLA alleles which may also genetically predispose individuals to cutaneous and neurologic injury with the common denominator being IgG4-mediated autoimmunity,¹¹ and thereby responsive to B cell depletion therapies.¹²

This dual development of autoantibody-mediated diseases, autoimmune diathesis, could be explained in the context of epitope spreading in which inappropriate exposure of receptors with cutaneous injury from AIBD could result in autoantibody generation. Indeed, LGI-1 and NMDA receptors are expressed in cutaneous structures, and bullous pemphigoid-related collagen XVII (BP180) proteins are localized in both neuronal and cutaneous structures thought to derive from common ectodermal lineage.³ One patient with anti-contactin-associated protein-like 2 (CASPR2) AE developed BP also suggesting a role for the neuronal cell adhesion molecule contactin 2/TAG1 although no evidence for cutaneous expression of this protein has been documented.⁷ Interestingly, the delayed timing between both autoimmune diseases and treatment with rituximab lends credence to re-emergence of novel autoreactive B cell clones.¹³ This was partially supported by our inability to detect anti-LGI-1 antibodies by ELISA in the pemphigus patient 1 year prior to the diagnosis of AE (data not shown). Of note, 2 of the 3 patients in this case series had previously received rituximab therapy which carries a black box warning for reactivation of JC virus and development of progressive multifocal leukoencephalopathy. Patient 2 did have negative CSF testing for JC virus, and all 3 patients did not demonstrate magnetic resonance imaging findings consistent with progressive multifocal leukoencephalopathy.

Other contributing factors may include local and systemic cytokine profiles for which IL17 A has been found to be increased in both skin and blood from

patients with AIBD,¹⁴ and recently in CSF from patients with non-NMDA receptor encephalitis,¹⁵ thus representing a potential common therapeutic target. Future studies including a larger patient subset across multiple geographic sites may provide further evidence to support and broaden these potential associations.

CONCLUSION

This study highlights a unique association of AIBD with AE with all our cases of AE occurring subsequent to AIBD. Additionally, these data support the concept of autoimmune diathesis which may result from loss of tolerance to shared neurocutaneous epitopes.

LIMITATIONS

This was a single-center study with retrospective nature with the inability to confirm all diagnoses generated from ICD 9/10 codes or confirm causal associations between inflammatory and autoimmune skin diseases and AE. Also, the full dataset of all patients identified through ICD codes may not be fully representative of the true number of patients with each dermatologic diagnosis, especially Alzheimer disease, which may be overrepresented through nonspecific dermatitis diagnoses. Finally, the sample size is relatively small and broad generalizations may be limited.

The authors would like to acknowledge Mr Robert B. Hawthorne, who provided guidance in conducting a query of the clinical data warehouse for the retrospective case-control study portion of this manuscript.

Conflict of interest

None disclosed.

REFERENCES

1. Karakioulaki M, Murrell DF, Kyriakou A, Patsatsi A. Investigation of comorbid autoimmune diseases in women with autoimmune bullous diseases: an interplay of autoimmunity and practical implications. *Int J Womens Dermatol*. 2022;8(3):e053.
2. Haitao R, Huiqin L, Tao Q, et al. Autoimmune encephalitis associated with vitiligo? *J Neuroimmunol*. 2017;310:14-16.
3. Ljubojevic S, Lipozenčić J. Autoimmune bullous diseases associations. *Clin Dermatol*. 2012;30(1):17-33.
4. Brick KE, Weaver CH, Savica R, et al. A population-based study of the association between bullous pemphigoid and neurologic disorders. *J Am Acad Dermatol*. 2014;71(6):1191-1197.
5. Kokkonen N, Herukka SK, Huilaja L, et al. Increased levels of the bullous pemphigoid BP180 autoantibody are associated with more severe dementia in Alzheimer's disease. *J Invest Dermatol*. 2017;137(1):71-76.
6. Fukata M, Yokoi N, Fukata Y. Neurobiology of autoimmune encephalitis. *Curr Opin Neurobiol*. 2018;48:1-8.

7. Zhao J, Wang C, Xu X, et al. Coexistence of autoimmune encephalitis and other systemic autoimmune diseases. *Front Neurol.* 2019;10:1142.
8. Siddiqui Z, Thien V, Patel M. SLE and anti-NMDA receptor encephalitis in an 18 year-old presenting with a skin rash. *J Anesth Crit Care Open Access.* 2017;8(4):00311.
9. Graus F, Titulaer MJ, Balu R, et al. A clinical approach to diagnosis of autoimmune encephalitis. *Lancet Neurol.* 2016; 15(4):391-404.
10. Kim TJ, Lee ST, Moon J, et al. Anti-LGI1 encephalitis is associated with unique HLA subtypes. *Ann Neurol.* 2017; 81(2):183-192.
11. Koneczny I, Yilmaz V, Lazaridis K, et al. Common denominators in the immunobiology of IgG4 autoimmune diseases: what do glomerulonephritis, pemphigus vulgaris, myasthenia gravis, thrombotic thrombocytopenic purpura and autoimmune encephalitis have in common? *Front Immunol.* 2021;11:605214.
12. Dalakas MC. Autoimmune neurological disorders with IgG4 antibodies: a distinct disease spectrum with unique IgG4 functions responding to anti-B cell therapies. *Neurotherapeutics.* 2022;19(3):741-752.
13. Lee DS, Rojas OL, Gommerman JL. B cell depletion therapies in autoimmune disease: advances and mechanistic insights. *Nat Rev Drug Discov.* 2021;20(3):179-199.
14. Chakievska L, Holtsche MM, Künstner A, et al. IL-17A is functionally relevant and a potential therapeutic target in bullous pemphigoid. *J Autoimmun.* 2019;96:104-112.
15. Levraut M, Bourg V, Capet N, et al. Cerebrospinal fluid IL-17A could predict acute disease severity in Non-NMDA-receptor autoimmune encephalitis. *Front Immunol.* 2021;12:673021.