



**EMORY**  
LIBRARIES &  
INFORMATION  
TECHNOLOGY

**OpenEmory**

## **Brucellosis Initially Misidentified as Ochrobacterium anthropi Bacteremia: A Case Report and Review of the Literature**

Srinvasa Nithin Gopalsamy, *Emory University*  
Aditi Ramakrishnan, *Emory University*  
Mustaf M Shariff, *Northside Hospital Gwinnett*  
Julie Gabel, *Georgia Department of Public Health*  
Skyler Brennan, *Georgia Department of Public Health*  
Cherie Drenzek, *Georgia Department of Public Health*  
[Monica Farley](#), *Emory University*  
[Robert Gaynes](#), *Emory University*  
[Emily Cartwright](#), *Emory University*

---

**Journal Title:** OPEN FORUM INFECTIOUS DISEASES

**Volume:** Volume 8, Number 10

**Publisher:** OXFORD UNIV PRESS INC | 2021-10-01, Pages ofab473-ofab473

**Type of Work:** Article | Final Publisher PDF

**Publisher DOI:** 10.1093/ofid/ofab473

**Permanent URL:** <https://pid.emory.edu/ark:/25593/w1hkv>

---

Final published version: <http://dx.doi.org/10.1093/ofid/ofab473>

### **Copyright information:**

© The Author(s) 2021. Published by Oxford University Press on behalf of Infectious Diseases Society of America.

This is an Open Access work distributed under the terms of the Creative Commons Attribution-NonCommercial-NoDerivatives 4.0 International License (<https://creativecommons.org/licenses/by-nc-nd/4.0/rdf>).

Accessed November 29, 2023 4:44 AM EST

# Brucellosis Initially Misidentified as *Ochrobactrum anthropi* Bacteremia: A Case Report and Review of the Literature

Srinivasa Nithin Gopalsamy,<sup>1</sup> Aditi Ramakrishnan,<sup>1</sup> Mustaf M. Shariff,<sup>2</sup> Julie Gabel,<sup>3</sup> Skyler Brennan,<sup>3</sup> Cherie Drenzek,<sup>3</sup> Monica M. Farley,<sup>4,5</sup> Robert P. Gaynes,<sup>4,5</sup> and Emily J. Cartwright<sup>4,5</sup>

<sup>1</sup>Division of Infectious Diseases, Department of Medicine, Emory University, Atlanta, Georgia, USA, <sup>2</sup>Department of Medicine, Northside Hospital Gwinnett, Lawrenceville, Georgia, USA, <sup>3</sup>Georgia Department of Public Health, Atlanta, Georgia, USA, <sup>4</sup>Division of Infectious Diseases, Department of Medicine, Emory University, Atlanta, Georgia, USA, and <sup>5</sup>Atlanta VA Medical Center, Decatur, Georgia, USA

Automated identification systems may misidentify *Brucella*, the causative agent of brucellosis, which may be re-emerging in the United States as the result of an expanding feral swine population. We present a case of *Brucella suis* likely associated with feral swine exposure that was misidentified as *Ochrobactrum anthropi*, a phylogenetic relative.

**Keywords.** *Brucella suis*; brucellosis; mass; matrix-assisted laser desorption-ionization; *Ochrobactrum anthropi*; spectrometry.

Brucellosis often manifests as a nonspecific febrile illness of varying duration, which can make diagnosis challenging, especially in nonendemic areas. Moreover, isolating *Brucella* in culture, the gold standard, requires biocontainment and highly skilled technical personnel to handle samples, while serologic tests, polymerase chain reaction (PCR)-based testing, and automated bacterial identification systems have suboptimal clinical sensitivity and specificity. We present a case of *Brucella suis* infection that was misidentified as *Ochrobactrum anthropi* bacteremia and review the related literature on misdiagnosis of brucellosis and its management implications. We also highlight an expanding epidemiologic risk factor for brucellosis and discuss treatment considerations and the risk of relapsed disease with delayed-onset complications, as demonstrated in this case.

Received 12 July 2021; editorial decision 8 September 2021; accepted 23 September 2021.

Correspondence: Srinivasa Nithin Gopalsamy, MD, Division of Infectious Diseases, Emory University School of Medicine, 49 Jesse Hill Jr Drive, Atlanta, GA 30303 (sgopals@emory.edu).

Open Forum Infectious Diseases® 2021

© The Author(s) 2021. Published by Oxford University Press on behalf of Infectious Diseases Society of America. This is an Open Access article distributed under the terms of the Creative Commons Attribution-NonCommercial-NoDerivs licence (<https://creativecommons.org/licenses/by-nc-nd/4.0/>), which permits non-commercial reproduction and distribution of the work, in any medium, provided the original work is not altered or transformed in any way, and that the work is properly cited. For commercial re-use, please contact journals.permissions@oup.com <https://doi.org/10.1093/ofid/ofab473>

## CASE

A 36-year-old man presented after a recent hunting and fishing trip in Alaska. Two days into the trip, he developed fever, night sweats, dizziness, and generalized arthralgias with no focal joint pain. He had headaches and photosensitivity but no focal weakness, numbness, or changes in vision or hearing. An episode of presyncope 3 weeks later prompted him to pursue further evaluation. His medical history was notable for systemic lupus erythematosus with lupus nephritis in remission last treated 4 years ago with mycophenolate, hydroxychloroquine, and prednisone. His surgical history was notable for bilateral total hip replacements 2 years ago for avascular necrosis due to prolonged steroid use. He reported no cigarette smoking, alcohol, or illicit drug use. He was monogamous with his wife; they lived in rural Georgia.

On presentation, he had a temperature of 38.0°C, heart rate of 105 bpm, blood pressure of 108/72 mmHg, respiratory rate of 17, and oxygen saturation of 98% on room air. Physical examination was notable for diaphoresis, shotty cervical lymphadenopathy, and L1–2 spine tenderness. There was no photophobia, nuchal rigidity, focal neurologic deficits, or hip tenderness. Laboratory tests demonstrated leukopenia of 2.4 k/cm<sup>3</sup> (42.2% segmented neutrophils, 45.5% lymphocytes, and 11.9% monocytes) with hemoglobin 13.9 g/dL and platelets 152 k/cm<sup>3</sup>. The alanine aminotransferase was 28 IU/L, aspartate aminotransferase 43 IU/L, and the C-reactive protein and erythrocyte sedimentation rate were elevated at 33.5 mg/L and 94 mm/h, respectively. The urinalysis demonstrated 2+ protein, 2 white blood cells per high power field, and <1 red blood cells per high power field. Lumbar and abdominal computed tomography imaging revealed splenomegaly and right L5 pars defect with hip visualization limited by streak artifact.

On admission, blood cultures were obtained. He was placed on empiric vancomycin and piperacillin-tazobactam but remained febrile with a maximum temperature of 39.4°C 4 days into the admission. The infectious diseases service was consulted and recommended serologies for *Coxiella*, *Tularemia*, *Brucella*, leptospirosis, and serum PCR for West Nile virus. Given the absence of meningismus or focal neurologic symptoms, lumbar puncture was deferred. On hospital day 3, blood cultures began growing a gram-negative organism. The isolate grew on blood and chocolate agars but not on MacConkey agar. The VITEK 2 (bioMérieux, Durham, NC, USA) automated system identified the isolate as *Ochrobactrum anthropi*. Given ongoing fever and reported automated antimicrobial susceptibility data [1], the antibiotic regimen was changed to levofloxacin; susceptibility was later confirmed via E-test (bioMérieux, Durham, NC, USA). A transthoracic echocardiogram showed no vegetations,

and his repeat blood cultures were without growth. The fevers resolved 2 days after the antibiotic change, and he was afebrile for 48 hours before discharge. His headache resolved and his arthralgias improved with no focal joint pain. He was discharged with a plan to complete a 2-week course of levofloxacin.

Following discharge, the *Brucella* immunoassay resulted in an IgM of 5.87 (negative if <0.8) and immunoglobulin G (IgG) of 1.92 with an antibody titer >1:1280 (Quest Diagnostics, San Juan Capistrano, CA, USA) [2]. The patient was contacted by the Georgia Department of Public Health (DPH) and reported field dressing a feral hog in Georgia and handling the raw meat without gloves. The DPH performed a *Brucella* microagglutination test (BMAT) that revealed a markedly elevated titer of 1:2560/1:320 reduced (IgG component), consistent with brucellosis.

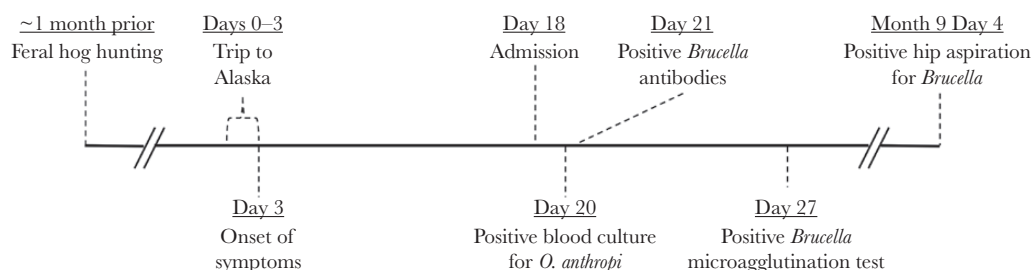
On the subsequent clinic visit, 2 months after discharge, the patient reported return of fevers, night sweats, and polyarthralgias. He was started on therapy with a 6-week course of doxycycline and rifampin. *Brucella* serology studies at this time showed an IgM of 2.51 and IgG of 3.85. Three months after completing the antibiotic course, the patient developed acute-onset left hip pain after trying to catch a baseball. The pain was worse with weight-bearing and ambulation. X-ray showed a fixed prosthesis with no acute fracture, while magnetic resonance imaging revealed a joint effusion. The synovial fluid aspirate had 15 011 white blood cells/mm<sup>3</sup> (56.7% neutrophils and 43% mononuclear cells) and grew *Brucella* on initial culture, and real-time PCR confirmed the isolate to be *Brucella suis* (Figure 1). The patient completed 4 weeks of gentamicin and restarted a prolonged course of doxycycline and rifampin. Notably, following completion of gentamicin, he reported difficulty with his balance that subsequently resolved in the absence of aminoglycoside therapy.

## DISCUSSION

This case highlights the limitations and pitfalls associated with the diagnosis and management of brucellosis, particularly in the context of misidentification as *Ochrobactrum anthropi*. *O. anthropi* and *Brucella* spp. are gram-negative organisms [3, 4] that are close phylogenetic relatives based on DNA, RNA,

and protein analyses [4], resulting in significant cross-reactivity on Western blot [5] and overlay in 16S ribosomal RNA (rRNA) sequence signatures [5, 6]. With such similarities between the 2 species, diagnostic overlap is a concern [7, 8]. The VITEK 2 automated system, used in this case, and matrix-assisted laser desorption/ionization time-of-flight (MALDI-TOF) mass spectrometry utilize a reference database to identify organisms. These automated systems are limited by the isolate-specific data available in the respective catalogues. Currently, only the VITEK 2 gram-negative bacteria card includes a *Brucella* species with *B. melitensis* [9], while *Ochrobactrum anthropi* is available routinely [9–11]. Table 1 summarizes the published reports of misidentification of *Brucella* species as *O. anthropi* with both older and updated automated systems. As *Brucella* is not regularly available on calorimetry or spectrometry databases, conventional culture techniques retain value. Though both *Brucella* and *O. anthropi* may grow on standard laboratory media including blood and chocolate agar, *Brucella* does not grow on MacConkey agar, while *O. anthropi* does. Thus, the American Society for Microbiology guidelines recommend that *Brucella* be identified by its growth patterns and state that automated systems have no role in the diagnosis of brucellosis [12].

Given the microbiological challenges in diagnosing brucellosis, an awareness of its local epidemiology may help maintain clinical suspicion. Four *Brucella* species can cause human disease: *B. melitensis* (isolated from sheep, goats, camels, and buffalo), *B. abortus* (from cattle), *B. canis* (from dogs), and *B. suis* (from swine) [3, 13]. While *B. suis* has been eradicated from the American commercial swine population [14], it is endemic among feral swine [15–17]. The geographic distribution of brucellosis, particularly *B. suis*, may be expanding with the increasing population and geographic distribution of feral swine in the United States. Feral swine are described as the most destructive invasive species nationally and are most prominent in the South [18, 19]. There are an estimated 4–6 million feral swine in the United States [20], with 200 000–600 000 reported in Georgia alone [21]. From 2010 to 2019, 42 probable and confirmed cases of brucellosis were reported to the Georgia DPH. Of the 26 confirmed cases, *B. suis* was the causative organism in 21. In at least 16 of the 21, feral swine exposure was documented. Hunting and



**Figure 1.** Timeline of patient's course. For the diagnostic tests, the day denoted refers to the collection date rather than the result date. Distance between events on timeline not to scale.

**Table 1. Cases of brucellosis initially misdiagnosed as *Ochrobactrum anthropi* infection**

Case	<i>O. anthropi</i> Identification Method	<i>Brucella</i> Antibody	Agglutination Test	PCR
Elsaghir et al., 2003 [28]	API 20NE	Positive	Positive	<i>B. melitensis</i>
Horvat et al., 2011 [7]	RapID NF Plus			<i>B. suis</i>
Carrington et al., 2012 [8]	RapID NF Plus VITEK 2	Positive		<i>B. suis</i>
Vila et al., 2016 [29]	VITEK 2	Positive	Positive	<i>B. suis</i>
Trépa et al., 2018 [30]	VITEK MS		Positive	<i>B. melitensis</i>
Poonawala et al., 2018 [31]	VITEK MS	Positive		<i>B. melitensis</i>
Khalilulina Ushakova et al., 2020 [32]	MALDI-TOF MS Bruker <sup>a</sup>		Positive	
Current case	VITEK 2	Positive	Positive	<i>B. suis</i>

Identification method refers to the modality used that initially identified the isolate as *O. anthropi*. Agglutination test includes serum agglutination test (including tube, plate, Rose-Bengal and Wright tests) and *Brucella* microagglutination test. PCR testing includes 16S rRNA sequencing.

Abbreviation: PCR, polymerase chain reaction.

<sup>a</sup>Later changed to *B. melitensis*

field dressing feral swine is a growing sport that is aimed at controlling the feral swine population but is increasingly identified as a risk factor for *B. suis* infection in the United States [22].

As with diagnosing brucellosis, subsequent management is challenging. Monotherapy is not recommended, and an extended antibiotic duration is often necessary. The preferred regimens are doxycycline combined with an aminoglycoside or rifampin. While this patient did not have meningismus, encephalopathy, myelitis, radiculitis, or neuritis, such neurologic complications should prompt cerebrospinal fluid evaluation and may warrant the addition of ceftriaxone or trimethoprim-sulfamethoxazole [3]. Although the aminoglycoside-containing regimen is associated with less treatment failure [23], doxycycline and rifampin are often selected due to their availability and convenience [24]. The patient's vestibular dysfunction symptoms also highlight the potential toxicity with aminoglycosides, though this is generally self-limited, as in this case [3]. Despite appropriate therapy, continued diligence is required as a course of brucellosis may involve treatment relapse, particularly among patients with positive blood cultures [25], within 6 months of therapy [26]. Relapse may manifest atypically with late-declaring organ complications; hardware such as a prosthetic joint is at high risk in the setting of bacteremia [27].

This case underscores the initial and long-term challenges of diagnosing and managing brucellosis. A thorough history is imperative, including recent and remote occupational and nonoccupational exposures, with a contemporary understanding of the epidemiology. Clinicians must maintain an elevated index of suspicion and utilize conventional microbiologic tools as automated identification systems may not suffice, as exemplified by the misidentification of *Brucella* species as *Ochrobactrum anthropi*. Upon diagnosing brucellosis, providers must be wary of relapsed or complicated disease with metastatic foci of infection, including organ and joint involvement, particularly in the presence of hardware.

## Acknowledgments

**Financial support.** TL1TR002382 provided protected time for S. N. Gopalsamy.

**Potential conflicts of interest.** All authors report no potential conflicts of interest relevant to this manuscript. All authors have submitted the ICMJE Form for Disclosure of Potential Conflicts of Interest. Conflicts that the editors consider relevant to the content of the manuscript have been disclosed.

**Patient consent.** This manuscript does not include factors necessitating patient consent.

**Author contributions.** Srinivasa Nithin Gopalsamy, MD—drafting manuscript, producing table and figure. Aditi Ramakrishnan, MD—drafting and revising manuscript. Mustaf M. Shariff, MD—drafting and revising manuscript. Julie Gabel, DVM, MPH—drafting and revising manuscript. Skyleer Brennan, MPH—drafting and revising manuscript. Cherie Drenzek, DVM, MS—drafting and revising manuscript. Monica M. Farley, MD—drafting and revising manuscript. Robert P. Gaynes, MD—drafting and revising manuscript. Emily J. Cartwright, MD—drafting, revising, and submitting manuscript.

## References

- Thoma B, Straube E, Scholz HC, et al. Identification and antimicrobial susceptibilities of *Ochrobactrum* spp. *Int J Med Microbiol* **2009**; 299:209–20.
- Quest Diagnostics. *Brucella* antibodies (IgG, IgM), EIA with reflex to agglutination. Available at: <https://testdirectory.questdiagnostics.com/test/test-detail/91068/brucella-antibodies-igg-igm-eia-with-reflex-to-agglutination?cc=MASTER>. Accessed 3 July 2021.
- Hanefi C, Gul HE. Brucellosis (*Brucella* species). In: *Mandell, Douglas, and Bennett's Principles and Practice of Infectious Diseases*. 9th ed. Elsevier Health Sciences, **2019**:2753–8.
- Holmes B, Popoff M, Kiredjian M, Kersters K. *Ochrobactrum anthropi* gen. nov., sp. nov. from human clinical specimens and previously known as group Vd. *Int J Syst Evol Microbiol* **1988**; 38:406–16.
- Velasco J, Romero C, López-Goñi I, et al. Evaluation of the relatedness of *Brucella* spp. and *Ochrobactrum anthropi* and description of *Ochrobactrum intermedium* sp. nov., a new species with a closer relationship to *Brucella* spp. *Int J Syst Bacteriol* **1998**; 48(Pt 3):759–68.
- Gee JE, De BK, Levett PN, et al. Use of 16S rRNA gene sequencing for rapid confirmatory identification of *Brucella* isolates. *J Clin Microbiol* **2004**; 42:3649–54.
- Horvat RT, El Atrouni W, Hammoud K, et al. Ribosomal RNA sequence analysis of *Brucella* infection misidentified as *Ochrobactrum anthropi* infection. *J Clin Microbiol* **2011**; 49:1165–8.
- Carrington M, Choe U, Ubillos S, et al. Fatal case of brucellosis misdiagnosed in early stages of *Brucella suis* infection in a 46-year-old patient with Marfan syndrome. *J Clin Microbiol* **2012**; 50:2173–5.
- bioMérieux. VITEK<sup>®</sup> 2 GN ID card. Available at: <https://www.biomerieux-diagnostics.com/technology/identification?page=1>. Accessed 10 August 2020.
- bioMérieux. VITEK<sup>®</sup> MS: healthcare. Available at: [https://www.biomerieux-usa.com/sites/subsidiary\\_us/files/k181412.ifu\\_final\\_sent001.pdf](https://www.biomerieux-usa.com/sites/subsidiary_us/files/k181412.ifu_final_sent001.pdf). Accessed 10 August 2020.

11. Bruker. MALDI-TOF mass spectrometry for fast, accurate and effective microbial identification. Available at: <https://bruker-marketing.actonsoftware.com/acton/form/4047/0016:d-0004/0/-/-/-/index.htm>. Accessed 10 August 2020.
12. Gilligan PH, York MK. *Sentinel Level Clinical Laboratory Guidelines for Suspected Agents of Bioterrorism and Emerging Infectious Diseases: Brucella Species*. American Society for Microbiology; **2016**.
13. Centers for Disease Control and Prevention. CDC Yellow Book 2020: Health Information for International Travel. Oxford University Press; **2017**.
14. Centers for Disease Control and Prevention. *Brucella suis* infection associated with feral swine hunting - three states, 2007-2008. *MMWR Morb Mortal Wkly Rep* **2009**; 58:618-21.
15. Gresham CS, Gresham CA, Duffy MJ, et al. Increased prevalence of *Brucella suis* and pseudorabies virus antibodies in adults of an isolated feral swine population in coastal South Carolina. *J Wildl Dis* **2002**; 38:653-6.
16. van der Leek ML, Becker HN, Humphrey P, et al. Prevalence of *Brucella* sp. antibodies in feral swine in Florida. *J Wildl Dis* **1993**; 29:410-5.
17. Zygmunt SM, Nettles VF, Shotts EB Jr, et al. Brucellosis in wild swine: a serologic and bacteriologic survey in the southeastern United States and Hawaii. *J Am Vet Med Assoc* **1982**; 181:1285-7.
18. Robbins J. Feral pigs roam the South. Now even northern states aren't safe. *New York Times*. 16 December **2019**.
19. Leiser OP, Corn JL, Schmit BS, et al. Feral swine brucellosis in the United States and prospective genomic techniques for disease epidemiology. *Vet Microbiol* **2013**; 166:1-10.
20. Bevins SN, Pederson K, Lutman MW, Gidlewski T, Deliberto TJ. Consequences associated with the recent range expansion of nonnative feral swine. *BioScience* **2014**; 64:291-9.
21. Towns/Union Extension Blog. Feral Hogs. **2019**. Available at: <https://site.extension.uga.edu/townsandunionag/2020/01/feral-hogs/>. Accessed 1 October 2021.
22. Centers for Disease Control and Prevention. *Brucellosis: Hunters Risks*. US Department of Health & Human Services; **2016**.
23. Yousefi-Nooraie R, Mortaz-Hejri S, Mehrani M, Sadeghipour P. Antibiotics for treating human brucellosis. *Cochrane Database Syst Rev* **2012**; 10:CD007179.
24. Ariza J, Bosilkovski M, Cascio A, et al; International Society of Chemotherapy; Institute of Continuing Medical Education of Ioannina. Perspectives for the treatment of brucellosis in the 21<sup>st</sup> century: the Ioannina recommendations. *PLoS Med* **2007**; 4:e317.
25. Ariza J, Corredoira J, Pallares R, et al. Characteristics of and risk factors for relapse of brucellosis in humans. *Clin Infect Dis* **1995**; 20:1241-9.
26. Roushan MR, Gangi SM, Ahmadi SA. Comparison of the efficacy of two months of treatment with co-trimoxazole plus doxycycline vs. co-trimoxazole plus rifampin in brucellosis. *Swiss Med Wkly* **2004**; 134:564-8.
27. Weil Y, Mattan Y, Liebergall M, Rahav G. *Brucella* prosthetic joint infection: a report of 3 cases and a review of the literature. *Clin Infect Dis* **2003**; 36:e81-6.
28. Elsaghir AAF, James EA. Misidentification of *Brucella melitensis* as *Ochrobactrum anthropi* by API 20NE. *J Med Microbiol* **2003**; 52:441-2.
29. Vila A, Pagella H, Vera Bello G, Vicente A. *Brucella suis* bacteremia misidentified as *Ochrobactrum anthropi* by the VITEK 2 system. *J Infect Dev Ctries* **2016**; 10:432-6.
30. Trêpa J, Mendes P, Gonçalves R, et al. *Brucella* vertebral osteomyelitis misidentified as an *Ochrobactrum anthropi* infection. *IDCases* **2018**; 11:74-6.
31. Poonawala H, Marrs Conner T, Peaper DR. The brief case: misidentification of *Brucella melitensis* as *Ochrobactrum anthropi* by matrix-assisted laser desorption ionization-time of flight mass spectrometry (MALDI-TOF MS). *J Clin Microbiol* **2018**; 56:e00914-17.
32. Khaliulina Ushakova T, Perera Lerin AI, Sahagún Pareja J, et al. Identification of *Brucella melitensis* as *Ochrobactrum anthropi* by MALDI-TOF MS. *Rev Esp Quimioter* **2020**; 33:223-4.