



Retrograde Pulmonary Vein Recanalization Using Transcatheter Electrosurgery

Saleem I. Almasarweh, *Emory University*

[James Kuo](#), *Emory University*

[Holly Bauser-Heaton](#), *Emory University*

[Vasilis Babaliaros](#), *Emory University*

[Dennis Kim](#), *Emory University*

Journal Title: JACC: Case Reports

Volume: Volume 4, Number 10

Publisher: Elsevier | 2022-05-18, Pages 592-595

Type of Work: Article | Final Publisher PDF

Publisher DOI: 10.1016/j.jaccas.2022.03.026

Permanent URL: <https://pid.emory.edu/ark:/25593/vz7rj>

Final published version: <http://dx.doi.org/10.1016/j.jaccas.2022.03.026>

Copyright information:

© 2022 The Authors

This is an Open Access work distributed under the terms of the Creative Commons Attribution 4.0 International License (<https://creativecommons.org/licenses/by/4.0/rdf>).

Accessed April 24, 2024 9:24 PM EDT

CASE REPORT

ADVANCED

CLINICAL CASE

Retrograde Pulmonary Vein Recanalization Using Transcatheter Electrosurgery



Saleem I. Almasarweh, MD,^a James A. Kuo, MD,^a Holly D. Bauser-Heaton, MD, PhD,^a Vasilis C. Babaliaros, MD,^b Dennis W. Kim, MD, PhD^a

ABSTRACT

Transcatheter electrosurgery is a wire-based technique used to traverse or cut tissue within blood-filled spaces using alternating current delivered by guidewires or catheters. The use of transcatheter electrosurgical techniques in the pediatric population has been limited. We are reporting the first case of retrograde pulmonary vein recanalization using transcatheter electrosurgery. (**Level of Difficulty: Advanced.**) (J Am Coll Cardiol Case Rep 2022;4:592-595) © 2022 The Authors. Published by Elsevier on behalf of the American College of Cardiology Foundation. This is an open access article under the CC BY license (<http://creativecommons.org/licenses/by/4.0/>).

HISTORY OF PRESENTATION

A 5-year-old, male patient with Trisomy 21 and prenatal diagnosis of Tetralogy of Fallot, initially underwent placement of a 4-mm right modified Blalock-Taussig shunt at 2 months of age. At 8 months of age, echocardiography showed evidence of pulmonary vein stenosis involving the left upper pulmonary

vein (LUPV) and the left lower pulmonary vein (LLPV). Initial cardiac catheterization also demonstrated stenosis of the right upper pulmonary vein (RUPV). He underwent angioplasties as well as stenting of the RUPV and LLPV before his complete “valve-sparing” tetralogy of Fallot repair with “sutureless” repair of the left pulmonary veins and transection of the RUPV stent at 21 months of age. Despite this, he continued to have progressive pulmonary vein disease requiring repeated pulmonary vein recanalizations/angioplasties as well as repeat RUPV and LLPV stenting. The LUPV became atretic and could not be recanalized, leaving the LLPV as the only egress of pulmonary venous flow from the left lung.

LEARNING OBJECTIVES

- To highlight that tools and techniques for coronary chronic total occlusion can be adapted for pediatric vascular occlusion therapies.
- To understand the role of established electrosurgical techniques in adult interventions being used in severe cases of pulmonary vein stenosis.
- To demonstrate that retrograde recanalization of atretic pulmonary veins can be performed if collateral vessels exist.

INVESTIGATIONS

He was brought to the catheterization lab, after a follow-up computed tomography angiography demonstrated occlusion of the stented LUPV and LLPV (**Figure 1**).

From the ^aDivision of Cardiology, Children’s Healthcare of Atlanta, Atlanta, Georgia, USA; and the ^bStructural Heart and Valve Center, Emory University Hospital, Atlanta, Georgia, USA.

The authors attest they are in compliance with human studies committees and animal welfare regulations of the authors’ institutions and Food and Drug Administration guidelines, including patient consent where appropriate. For more information, visit the [Author Center](#).

Manuscript received November 16, 2021; revised manuscript received February 24, 2022, accepted March 28, 2022.

MANAGEMENT

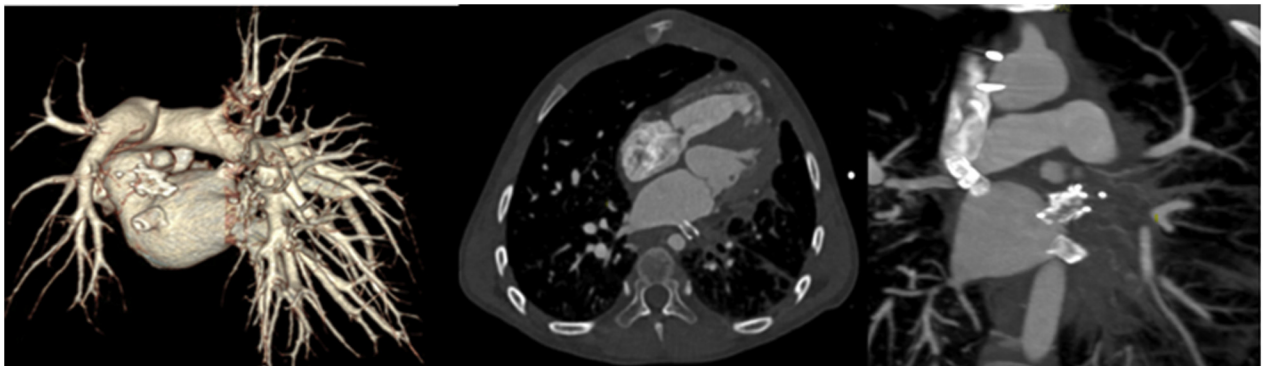
Right femoral venous access was obtained using a 5-F sheath, after obtaining access to the left atrium (LA), a 6.5-F Destino Twist steerable guiding sheath (Oscor Inc.) was advanced to the LA. Angiography showed complete occlusion of the LLPV stent; however, a guidewire was able to be advanced to the distal left lower segmental branch (Video 1). After balloon angioplasty and improvement of flow, it was noticed that another posterior-lateral major segmental LLPV branch had a long segment atresia with discontinuity to the LLPV stent with the distal vessel supplied by collaterals from the more medial branches (Video 2, Figure 2). Multiple attempts that were made to obtain access to this branch from the LA through the LLPV stent were unsuccessful. Through a venovenous collateral vessel, a Hi-Torque Whisper wire (Abbott Inc.) was able to be passed retrograde back toward the LLPV stent over which an Echelon 10 microcatheter, a Nitinol braided microcatheter typically used in small vessel peripheral and neurovascular interventions (Medtronic), was then able to traverse through the venous collateral vessel into the major branch and back toward the stent more medially (Figure 3). However, retrograde reentry into the LLPV stent was not able to be obtained. Although the direction of blood flow is toward the LA from the peripheral segmental pulmonary veins, we use the term “retrograde” to indicate intervention directed back

toward the pulmonary vein ostium to be consistent with this term being used for total occlusion coronary artery interventions that are performed via collateral vessels to reestablish flow to the occluded segment. Electrosurgical wire passage (Video 3) was performed by advancing the distal end of a straight tip Balance Middleweight coronary guidewire, protruding just beyond the microcatheter catheter tip with the backend of the guidewire clamped to the electrosurgery pencil with a hemostat, 50 W was delivered for <2 seconds using the electrosurgery pen and generator (Medtronic Valleylab FT10 Energy Platform). The guidewire easily was advanced across the tissue passing through the LLPV stent into the LA and the wire was able to be passed to the RUPV (Figure 4). Because the electrosurgery wire technique directs energy to such a small area in contact with the 0.014-inch-diameter wire, thermal exposure to other adjacent structures is avoided. Retrograde serial balloon angioplasties of the recanalized segmental pulmonary vein were performed using 1.5-mm and 3-mm noncompliant coronary angioplasty balloons (Video 4), followed by kissing balloon angioplasty of the LLPV stent into the 2 major peripheral branches using two 3-mm noncompliant coronary balloons (Video 5). After this, continuity to LA was established without evidence of vessel injury or contrast extravasation (Videos 6A and 6B, Figure 5).

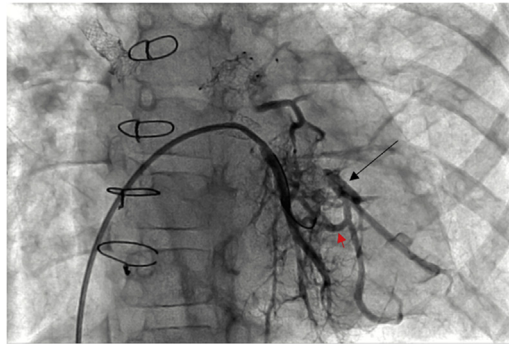
ABBREVIATIONS AND ACRONYMS

LA = left atrium
LLPV = left lower pulmonary vein
LUPV = left upper pulmonary vein
RUPV = right upper pulmonary vein

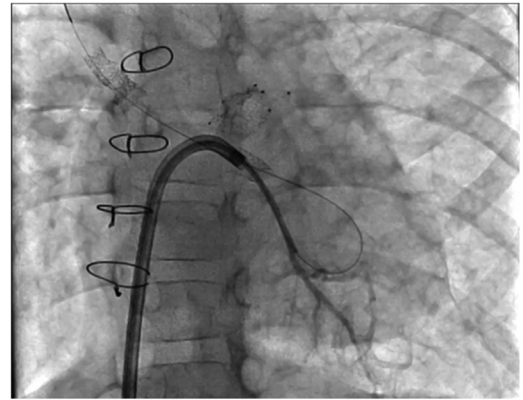
FIGURE 1 Computed Tomography Angiography



Computed tomography angiography before intervention, demonstrating complete occlusion of left upper pulmonary vein and left lower pulmonary vein stents.

FIGURE 2 Angiogram

Straight anteroposterior projection of hand injection in the left lower pulmonary vein after initial balloon angioplasty, demonstrating long segment atresia from the peripheral bifurcation point to the pulmonary vein stent of a posterior-lateral major segmental branch of left lower pulmonary vein branch (**arrow**) supplied by collaterals (**red arrowhead**) from the more medial branches.

FIGURE 4 Electrosurgical Wire Position

Straight anteroposterior (AP) projection, demonstrating the position of the balance middleweight wire in the right upper pulmonary vein after successful electro-surgical wire passage.

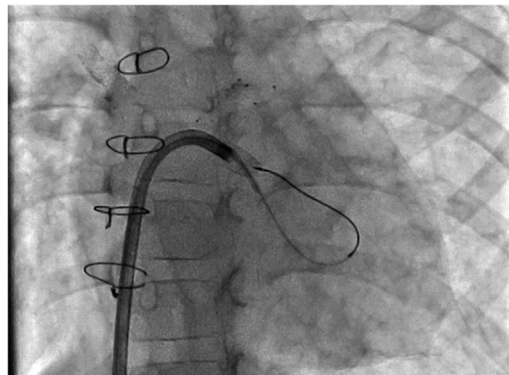
FOLLOW-UP

Patient was discharged home the next morning with no clinical evidence of esophageal or phrenic nerve injury.

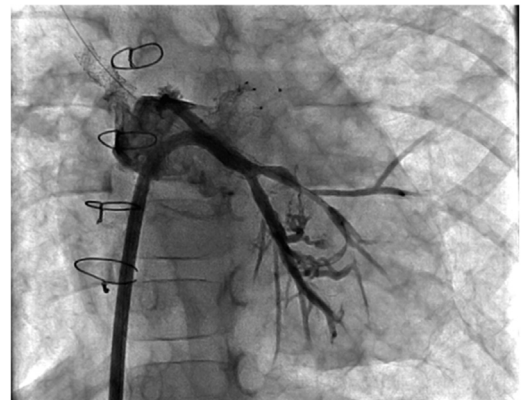DISCUSSION

Pulmonary vein stenosis in children is a challenging disease, because of its progressive nature,^{1,2} high

reintervention rates after percutaneous balloon and stent angioplasty, and poor long-term survival.^{3,4} Transcatheter electro-surgery is a technique used to traverse or cut tissue, within blood-filled spaces, using alternating current directed by guidewires and catheters.⁵ In contrast to adults, the use of transcatheter electro-surgical techniques in the pediatric population has been limited. The Baylis radio-frequency perforating system has been used to

FIGURE 3 Microcatheter Position

Straight anteroposterior projection, demonstrating the Echelon 10 microcatheter position after it was advanced retrograde through the venovenous collateral.

FIGURE 5 Final Result

Straight anteroposterior projection of a hand injection in the left lower pulmonary vein, after recanalization of the atretic branch, demonstrating continuity into the left atrium.

perforate atretic pulmonary valve plates in pulmonary atresia intact ventricular septum,⁶⁻⁸ and for atrial septal puncture in newborns with hypoplastic left heart syndrome and intact atrial septum,⁸⁻¹⁰ but requires a specialized system with a relatively large microcatheter needed. We report a novel procedure to recanalize atretic pulmonary veins via a retrograde approach and using electro-surgery to transverse atretic tissue for vessel recanalization in a pediatric patient.

FUNDING SUPPORT AND AUTHOR DISCLOSURES

The authors have reported that they have no relationships relevant to the contents of this paper to disclose.

ADDRESS FOR CORRESPONDENCE: Dr Saleem Almasarweh, Children's Healthcare of Atlanta, Department of Cardiology, 1405 Clifton Road NE, Atlanta, Georgia 30322, USA. E-mail: almasarwehs@kidsheart.com.

REFERENCES

1. Kalfa D, Belli E, Bacha E, et al. for the European Congenital Heart Surgeons Association. Outcomes and prognostic factors for postsurgical pulmonary vein stenosis in the current era. *J Thorac Cardiovasc Surg*. 2018;156:278-286.
2. Kalfa D, Belli E, Bacha E, et al., for the European Congenital Heart Surgeons Association. Primary pulmonary vein stenosis: outcomes, risk factors, and severity score in a multicentric study. *Ann Thorac Surg*. 2017;104:182-189.
3. Peng LF, Lock JE, Nugent AW, Jenkins KJ, McElhinney DB. Comparison of conventional and cutting balloon angioplasty for congenital and postoperative pulmonary vein stenosis in infants and young children. *Catheter Cardiovasc Interv*. 2010;75:1084-1090.
4. Balasubramanian S, Marshall AC, Gauvreau K, et al. Outcomes after stent implantation for the treatment of congenital and postoperative pulmonary vein stenosis in children. *Circ Cardiovasc Interv*. 2012;5:109-117.
5. Khan JM, Rogers T, Greenbaum AB, et al. Transcatheter electro-surgery: JACC State-of-the-Art Review. *J Am Coll Cardiol*. 2020;75(12):1455-1470. <https://doi.org/10.1016/j.jacc.2020.01.035>
6. Rosenthal E, Qureshi SA, Chan KC, et al. Radiofrequency-assisted balloon dilatation in patients with pulmonary valve atresia and an intact ventricular septum. *Br Heart J*. 1993;69:347-351.
7. Justo RN, Nykanen DG, Williams WG, Freedom RM, Benson LN. Transcatheter perforation of the right ventricular outflow tract as initial therapy for pulmonary valve atresia and intact ventricular septum in the newborn. *Cathet Cardiovasc Diagn*. 1997;40:408-413.
8. Wang JK, Wu MH, Chang CI, Chen YS, Lue HC. Outcomes of transcatheter valvotomy in patients with pulmonary atresia and intact ventricular septum. *Am J Cardiol*. 1999;84:1055-1060.
9. Hill SL, Mizelle KM, Vellucci SM, Feltes TF, Cheatham JP. Radiofrequency perforation and cutting balloon septoplasty of intact atrial septum in a newborn with hypoplastic left heart syndrome using transesophageal ICE probe guidance. *Catheter Cardiovasc Interv*. 2005;64:214-217.
10. Gordon BM, Levi DS, Shannon KM. Electro-surgical energy in combination with a transseptal needle: a novel method for the creation of an atrial communication in hypoplastic left heart syndrome with intact atrial septum. *Catheter Cardiovasc Interv*. 2009;73:113-116.

KEY WORDS congenital heart disease, pediatric, pulmonary vein stenosis, transcatheter electro-surgery

APPENDIX For supplemental videos, please see the online version of this paper.