



Autologous Fat Injection for Augmentation Rhinoplasty: A Systematic Review.

Seied Omid Keyhan, *Maxillofacial Surgery & Implantology & Biomaterial Research Foundation, Tehran, Iran.*

Shaqayeq Ramezanzade, *Maxillofacial Surgery & Implantology & Biomaterial Research Foundation, Tehran, Iran.*

Behnam Bohluli, *Oral and Maxillofacial Surgery, University of Toronto, Toronto, Ontario, Canada.*

Hamid Reza Fallahi, *Maxillofacial Surgery & Implantology & Biomaterial Research Foundation, Tehran, Iran.*

Sanaz Mirzahoseini, *Maxillofacial Surgery & Implantology & Biomaterial Research Foundation, Tehran, Iran.*

[Foad Nahai](#), *Emory University*

Journal Title: Aesthet Surg J Open Forum

Volume: Volume 3, Number 2

Publisher: Oxford University Press | 2021-06, Pages ojab010-ojab010

Type of Work: Article | Final Publisher PDF

Publisher DOI: 10.1093/asjof/ojab010

Permanent URL: <https://pid.emory.edu/ark:/25593/vvxvt>

Final published version: <http://dx.doi.org/10.1093/asjof/ojab010>

Copyright information:

© 2021 The Aesthetic Society.

This is an Open Access work distributed under the terms of the Creative Commons Attribution-NonCommercial 4.0 International License (<https://creativecommons.org/licenses/by-nc/4.0/rdf>).

Accessed December 2, 2023 10:29 AM EST

Autologous Fat Injection for Augmentation Rhinoplasty: A Systematic Review

Seied Omid Keyhan, DDS, OMFS; Shaqayeq Ramezanzade, DDS; Behnam Bohluli, DMD, FRCD(C); Hamid Reza Fallahi, DDS, OMFS; Sanaz Mirzahoseini, PhD; and Foad Nahai, MD, FACS

Aesthetic Surgery Journal Open Forum 2021, 1–12

© 2021 The Aesthetic Society.

This is an Open Access article distributed under the terms of the Creative Commons Attribution-NonCommercial License (<http://creativecommons.org/licenses/by-nc/4.0/>), which permits non-commercial re-use, distribution, and reproduction in any medium, provided the original work is properly cited. For commercial re-use, please contact journals.permissions@oup.com

DOI: 10.1093/asjof/ojab010

www.asjopenforum.com

OXFORD
UNIVERSITY PRESS

Abstract

Background: Autologous fat has become more frequently used for nasal volume augmentation and nasal correction. Nasal lipofilling refers to the use of injectable autologous fat grafts for nonsurgical aesthetic corrections.

Objectives: This systematic review aims to assess the satisfaction, complication, and retention rates of fat injection in nasal shape corrections.

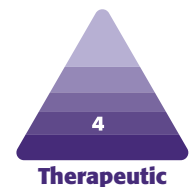
Methods: The authors searched PubMed/Medline and Google Scholar up to and including October 2020 with no time and language restrictions for pertinent materials. Two authors conducted a duplicate searching process independently to determine proper materials based on the inclusion and exclusion criteria. One author retrieved the following data from the finally included studies based on a predefined checklist worksheet.

Results: The included studies report data from a total of 564 patients undergoing nasal fat injection in 12 studies. The mean score in our included materials was 6.08 with a range of 4 to 7 scores. In most of our included materials, no complication was reported for the peri/postsurgical period. Although some papers reported manageable complications such as an insufficient volume or decreased volume by resorption, tip excess and supratip fullness, and mild displacement, more than half of our included materials reported on patient satisfaction with aesthetic results of fat injection. The satisfaction rates were mostly high and ranged from 63% to 100%.

Conclusions: Autologous fat injection is an effective and minimally invasive treatment for nasal aesthetic and contour correction with a high satisfaction rate and low complication rate. Clinical expertise is essential to have a safe injection and to minimize the potential complications.

Level of Evidence: 4

Editorial Decision date: February 19, 2021; online publish-ahead-of-print March 2, 2021.



Surgical rhinoplasty remains the first indication and the gold standard for patients seeking higher aesthetic

nasal shape. Although there is an increasing demand for

Dr Keyhan is a founder and director and Dr Ramezanzade is a practitioner, Maxillofacial Surgery & Implantology & Biomaterial Research Foundation, Tehran, Iran. Dr Bohluli is a surgeon, Oral and Maxillofacial Surgery, University of Toronto, Toronto, Ontario, Canada. Dr Fallahi is a founder and director and Dr Mirzahoseini is a PhD engineer, Maxillofacial Surgery & Implantology & Biomaterial Research Foundation, Tehran, Iran. Dr Nahai is an adjunct professor,

Emory University, Atlanta, GA, USA and is the Editor-in-Chief of *Aesthetic Surgery Journal*.

Corresponding Author:

Dr Shaqayeq Ramezanzade, Maxillofacial Surgery & Implantology & Biomaterial Research Foundation, Yousef Abad, Mouj Street, Tehran, Iran 1433843183.

E-mail: shaqayeq.ramezanzade@gmail.com

aesthetic improvement of nasal shape without undergoing surgical procedures, nonsurgical rhinoplasty procedures involve dorsal augmentation, nasal sidewall deformity corrections, alteration in tip projection/rotation, nose elongation, and deep radix correction.¹ Different injectable fillers such as autologous (autologous fat and cartilage),² heterogeneous (bovine collagen), and alloplastic (silicone, methylmethacrylate spheres, polytetrafluoroethylene, hyaluronic acid, and calcium hydroxyapatite)¹ fillers have been used to refine the shape of the nose by external molding mostly with local or no anesthesia and with minimal recovery time.

Synthetic injectable materials such as hyaluronic acid and calcium hydroxyapatite are more commonly used as they preclude the need for a donor site and further morbidities. They also have routine office performance, and no general anesthesia or sedation is needed. Although, there have been cases of necrosis after injection of alloplastic fillers injection.

The autologous fillers like fat grating should be preferred to alloplastic and heterogeneous injections. Fat injection is a relatively low-morbidity and low-risk nonsurgical procedure that has been used for over 20 years in facial soft tissue corrections.³ Augmentation using the autologous fat injection is readily available, biocompatible, involves minor invasion and is associated with low harvesting-site morbidity, and brings a natural appearance. However, fat grafts are known as unpredictable procedures.⁴ The complications are rare but a handful of cases have experienced serious complications such as permanent blindness after fat emboli.^{5,6} Fat injection camouflages slight to moderate aesthetic imperfections (not very marked nose deformities or respiratory malfunctions).³ Despite the growing popularity of fat injection in the aesthetic improvement of nasal shape, there is no general agreement on the advantages and disadvantages of fat injection. This systematic review aims to assess the satisfaction, complication, and retention rates of fat injection in nasal shape corrections.

METHODS

PRISMA Registration

We followed the PRISMA guidelines for conducting systematic review in this work and specified and registered our search protocol at PROSPERO (International prospective register of systematic reviews) with registration no. CRD42020219380.

PICO Question

Patient: Patients with nasal deformities undergoing augmentation rhinoplasty using fat transplantation.

Intervention: Augmentation rhinoplasty using fat transplantation.

Comparison: None.

Outcome: Injection location, aesthetic results, and satisfaction and complication rates of fat injection.

Search Strategy

We searched PubMed/Medline (United States National Library of Medicine [NLM], Bethesda, MD) and Google Scholar (Google, Mountain View, CA) up to and including October 2020 with no time and language restrictions for pertinent materials. The reference list of included studies was also hand searched for potential studies. The following search strategies were advocated for each database:

1. PubMed/Medline: ((((((rhinoplasty[Title/Abstract]) OR (revisional rhinoplasty[Title/Abstract])) OR (augmentation[Title/Abstract])) OR (augmentation rhinoplasty[Title/Abstract])) OR (sequelae of rhinoplasty [Title/Abstract])) AND (((((autologous fat[Title/Abstract]) OR (Autologous fat grafting[Title/Abstract])) OR (Lipofilling[Title/Abstract])) OR (Microcannula[Title/Abstract])) OR (Fat injection[Title/Abstract])).
2. Google Scholar.

Concept 1: allintitle: "rhinoplasty" OR "revisional rhinoplasty" OR "dorsal augmentation" OR "sequelae of rhinoplasty" "autologous fat."

Concept 2: allintitle: "rhinoplasty" OR "revisional rhinoplasty" OR "dorsal augmentation" OR "sequelae of rhinoplasty" "Fat."

Inclusion and Exclusion Criteria

The inclusion criteria were:

1. Controlled and non-controlled trials, prospective and retrospective cohort studies, and case series on the aesthetic results and/or satisfaction, and/or complication rates of fat injection in nasal shape corrections.
2. Papers written in English only.
3. Human studies.

The exclusion criteria were (the reasons for excluding articles were also recorded in [Table 1](#)):

1. Studies reporting only Ratios (Risk Ratio, Odds Ratio, Hazard Ratio) instead of the absolute outcomes were not of our interest.
2. Reports of nasal augmentation rhinoplasty with using grafts and materials other than fat.
3. Case reports, technical notes, and case series with less than 10 cases were excluded.
4. Studies with less than 5 participants.

Table 1. Excluded Studies With Reasons

Study (first author/year)	Reason for exclusion
Jie (2019) ⁷	Not English
Nguyen (2014) ⁸	Not English
Yan (2010) ⁹	Not English
Chen (2013) ¹⁰	Not English
Na (2011) ¹¹	Not English
Sinrachtanant (2012) ¹²	Case report
Kim (2013) ¹³	Technical note
Piotet (2015) ¹⁴	Fat injection not for aesthetic nasal correction
Erdogan (2002) ¹⁵	No fat injection
Nakakita (1999) ¹⁶	Not dicted cartilage (alloderm & implant)
Bektas (2020) ¹⁷	Using materials other than fat
Sterodimas (2013) ¹⁸	Case report
Ciloglu (2015) ¹⁹	Case report

Study Selection

Two authors conducted a duplicate searching process independently to determine proper materials based on the inclusion and exclusion criteria. Instances of divergence of opinion were resolved by consulting a third author. The full-text version of papers was obtained for all titles that appeared to meet the inclusion criteria or in case of any hesitancy. After that, each paper was studied at least twice by one author (S.R.).

Data Extraction

One author retrieved the following data from the finally included studies based on a predefined checklist worksheet and 2 authors supervised the accuracy. In case of missing data or any hesitancy, we contacted the corresponding author of the study through email, as the poorly reported outcomes of included materials could thread the validity of our work. The following data were extracted: first author, year of publication, country of origin, study type, mean age, sex, number of cases, mean follow-up (range), fat harvesting site, outcome measurement tools, rates of complications, donor-site morbidities, revisional surgical procedures, and satisfaction rate (percent). The injection location, aesthetic results, and satisfaction and complication rates of fat injection.

Risk of Bias Assessment

The methodological quality and synthesis of case series and case reports by Murad et al were used for bias

assessment.²⁰ There were 8 questions in the following domains: selection, ascertainment, causality, and reporting.

RESULTS

Study Selection

Figure 1 illustrates the PRISMA flow diagram for the study selection at different levels. In total, 675 papers were found throughout the initial search. After duplication removal, 649 papers remained, which titles and abstracts were assessed. Of those, 27 were submitted to full-text analysis. At this level, 15 papers were excluded with a reason (Table 1), and 12 papers were finally included.

Study Characteristics

The characteristics of the studies included in this review are presented in Table 2. The included studies report data from a total of 564 patients undergoing nasal fat injection in 12 studies; 302 cases were female and 44 cases were male. The gender was not specified in 218 cases. The mean age of patients was 30.02 with a range of 14 to 76.

In 493 cases, the fat injection was the primary procedure, and, in 57 patients, it was a secondary/tertiary procedure. One paper (14 patients) did not report the primary or secondary status of the procedure.²⁶ The fat harvesting sites were abdomen in 6 studies,^{3,24,25,29,31,32} Knees,^{22,27} inner thigh,²³ and not reported.^{21,26} Studies were conducted in the following countries: China,²³ United States,^{3,21,24,27-29,31,32} France,²² Spain,²⁵ Turkey,²⁶ and Taiwan.³⁰

Duration of Follow-Ups

The mean follows up were reported by 7 papers^{3,21,25,27,29,30,33} and the total mean follow-up was 1.67 years. The follow-up range started from 2 weeks to 5.2 years.

Results of Risk of Bias Assessment

The mean score in our included materials was 6.08 with a range of 4 to 7 scores (Table 3).

The Injection Location

Different deficient sites were treated with the autologous fat transplant. Some papers reported the specific fat injection location in nose or paranasal areas as follows: nasal dorsum,^{22,25,27,28,30,32} tip,^{24-26,28} radix,^{25,32} and glabella.²⁵

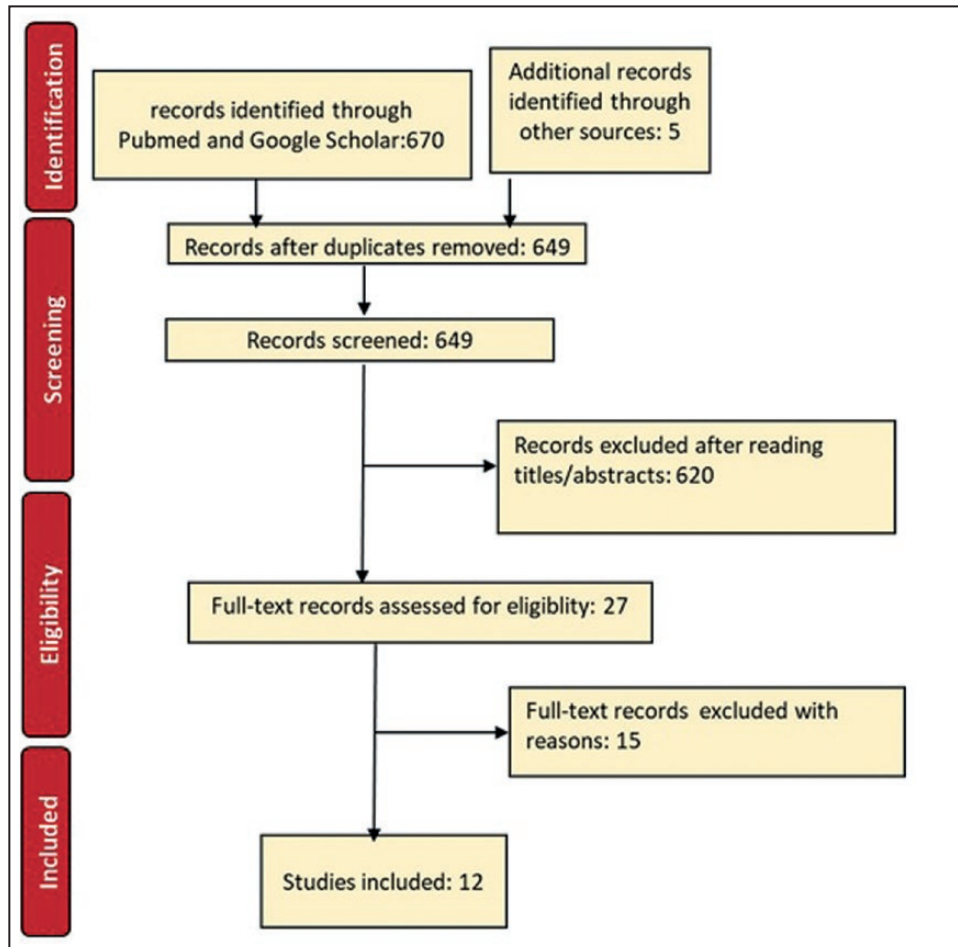


Figure 1. The PRISMA flowchart of included studies.

Aesthetic Results and Patients' Satisfaction

The reported satisfaction was as follows: 8 papers reported the patients' satisfaction rates: Cárdenas and Carvajal assessed 78 patients and reported 68 excellent, 9 good, and 1 unsatisfactory results.²⁷ In the study by Baptista et al, only 2 cases out of the 20 were not satisfied with the result and required a second session.²² Lin et al reported 100% satisfaction for all 13 cases included and no further injection was required.³⁰ After 6 months of follow-up, 4 cases were assessed and the fat graft retention rate was 40%. The overall patient satisfaction was reported as 80%,²⁵ 87.6%,²⁶ and 63.1%³ in 3 included studies. Also in 2 studies, most of the cases reported a high degree of satisfaction for the aesthetic results of autologous fat grafting but the exact percent was not reported.^{23,29} The remaining 4 papers did not mention patient satisfaction directly.^{21,24,28,32}

Complication Rates of Fat Injection

The complications reported were as follows: most of the papers experienced no complication while/during the

postoperative period.^{3,21,22,24,26,27,29,30,32} Although, some reported mild complications that did not require additional treatment or surgical interventions. Monreal reported one combined (fat injection plus surgical rhinoplasty) case of mild displacement, which was further treated without severe consequences.²⁵ In the study by Yuksel et al, of 59 cases 3 had tip excess and 4 had supratip fullness (all of them due to vertical shift).²⁸ Likewise, the height was insufficient in 3 cases. The fat grafting was repeated 1 to 3 times in their study differentially. One paper did not directly mention the assessment of complications.²³

DISCUSSION

Autologous fat has become more frequently used for nasal volume augmentation and nasal correction.³⁴ Nasal lipofilling refers to the use of injectable autologous fat grafts for nonsurgical aesthetic corrections. Although surgical rhinoplasty is still the treatment of choice, nasal lipofilling is replacing some of the traditional rhinoplasty procedures and gaining attention as it has a relatively good safety profile, is more cost-effective, does not cause

Table 2. The Characteristics of Included Studies

First author (y), country of origin, language	Study type	Measurement	Mean follow-up (range)	Number of cases (primary/secondary)	Complication/satisfaction	Mean age / sex	Fat harvesting site	Overall efficacy	Relative safety
Kornstein ²¹ (2015), USA, English	Retro-spective review	Reviewed pre-operative and postoperative images	FG group; mean follow-up, 3.3 y FG + R group; mean follow-up, 5.2 y.	26 patients (secondary rhinoplasty) underwent fat grafting alone, and 19 had fat grafting plus rhinoplasty	No complications occurred in either group	The FG group comprised 24 women and 2 men, with a mean age of 44.15 y (range: 23-60 y) The FG + R group consisted of 17 women and 2 men, with a mean age of 39.10 y (range: 27-63 y)	NR	Autologous fat grafting to the forehead/ glabella/ radix complex and pyriform aperture is a reliable method to favorably influence the nasofrontal and nasolabial angles, respectively. Such treatment optimizes the interplay between the nose and the adjacent facial features, enhancing the overall aesthetics.	Fat grafting provides a safe and long-lasting means of controlling the position of the radix
Baptista ²² (2013), France	Retro-spective review	Reviewed pre-operative and postoperative images.	Followed up for 18–24 mo	20 patients (15 cases of primary and 5 cases of secondary in rhinoplasty)	In our practice, we have never had complications with the use of adipose tissue and the literature confirms the reliability of this procedure. 18 had satisfactory aesthetic results after 1 procedure and 2 required a second session.	The mean age of the patients was 53 y. (women)	Fat was harvested at the following donor sites: the internal side of the knees and the subumbilical region	In patients who undergo multiple procedures, lipofilling can be a simple and reliable alternative to correct imperfections following rhinoplasty. In our experience, the smaller cannulae used for the microinjection of adipose fat present numerous advantages. The procedure can be performed under local anesthesia. It is more precise and less traumatic, which means that there is very little or no ecchymosis and edema, thereby enabling patients to immediately return to their normal lives.	NR
Xu ²³ (2019), China, English	Retro-spective review	The preoperative and postoperative states were evaluated and photograph documentations.	12 to 24 mo	9 patients (all cases secondary operations.)	Most common complications are infection and capsular contracture. A high degree of satisfaction was obtained with a mean dose of 1.0 mL (range 0.5-1.5 mL), effectively avoiding complicated operation.	Mean age not reported (8 females and 1 male)	The inner thigh as the donor site	All 9 patients achieved nasal aesthetic and functional improvement, and reduction for pain, stiff, irregular, relief, and pliability ($P < 0.05$) in POSAS scores was statistically significant. The efficiency is limited on the short nose deformity, and repeated injection is needed for improvement	The real mechanism of fat grafting in scar is still unclear.

Table 2. Continued

First author (y), country of origin, language	Study type	Measurement	Mean follow-up (range)	Number of cases (primary/secondary)	Complication/satisfaction	Mean age / sex	Fat harvesting site	Overall efficacy	Relative safety
Gabrick ²⁴ (2019), USA, English	Retrospective	Three-dimensional (3D) images were analyzed employing mirror. Data collected included demographic information, surgical indications, operative details, and 3D clinical photographs.	Mean follow-up was similar between cohorts with 1.3 y (range: 0.1-5.8 y) in the nonfat grafted cohort and 1.8 y (range: 0.2-5.1 y) in the fat grafted cohort.	62 patients (primary open rhinoplasty)	Complications rates were negligible for the study. There was zero incidence of infection, bleeding, or postoperative obstruction. One patient in the fat grafted cohort underwent revision for alae contouring and one patient in the nonfat grafted cohort underwent revision due to post-rhinoplasty nasal trauma. There was zero incidence of vascular damage or cellulitis in the donor or recipient sites for the autologous fat grafting portion of the case.	The mean age of patients in the study was 35.6 y (range: 16-76 y); 38 (61%) were female and 24 (39%) were male.	Fat was harvested from the abdomen and/or thigh	Autologous fat grafting is a useful adjunct to rhinoplasty and is associated with a significantly lower amount of ecchymoses in the acute postoperative period.	Autologous fat is a safe and effective soft tissue filler. Recent evidence also suggests improved wound healing and immune modulation with fat grafting.
Monreal ²⁵ (2011), Spain, English	Case series	By comparison with preoperative and postoperative control photographs	A maximum follow-up period of 14 mo (mean, 7 mo). Follow-up visits were scheduled at 7 d, 15 d, 3 mo, 6 mo, and 12 mo	33 patients (the experience covers primary treatments of noses not treated by surgery, treatment of post-rhinoplasty deformities, and combination fat grafting and rhinoplasties.)	The initial analysis of postoperative results showed a good to high level of patient satisfaction, particularly in primary cases, with virtually no complications or severe side effects. The current series of patients experienced no complications or untoward results that required additional treatment or surgical interventions. Only in one combined case did minimal displacement of the grafted fat in the radix occur, probably caused during the nasal splinting.	NR	Fat harvested from the lower abdomen or inner thighs.	Autologous fat grafting is an effective and reliable technique for aesthetic and reconstructive nose reshaping for patients who refuse surgical treatments. Although optimal results can be achieved with this technique, they are not comparable with those obtained by surgical rhinoplasties	Fat grafts have demonstrated the ability to release tightly adherent skin in a way that provides better conditions and makes secondary surgical rhinoplasty safer.
Kao ³ (2016), USA, English	Case series	Most of the patients were monitored beyond this duration. Photographs were taken at each visit for comparisons over time.	Patients received follow-up for an average of 19 mo (range: 6-42 mo). All patients received routine follow-up at an outpatient clinic at 1, 3, and 6 mo postoperatively.	198 patients (all primary)	There were no major complications.	Mean age not reported (180 women and 18 men)	The lower abdomen	With years of extensive research and refinement of surgical techniques, structural fat grafting has become a reliable treatment strategy with acceptable clinical outcomes. The results of this study support MAFT as an appropriate fat transfer strategy for Asian patients undergoing primary augmentation rhinoplasty.	Fat survival and retention rates are unpredictable, and complications such as abscesses, cysts, nodulation, and neurovascular injury may occur.

Table 2. Continued

First author (y), country of origin, language	Study type	Measurement	Mean follow-up (range)	Number of cases (primary/secondary)	Complication/satisfaction	Mean age / sex	Fat harvesting site	Overall efficacy	Relative safety
Ozer ²⁶ (2019), Turkey, English	Retrospective review	NR	Patients were followed up for a minimum of 9 mo.	14 patients	No major complications (eg, infection, skin necrosis, nodulation, fibrosis, calcification, asymmetry, or vascular insults) were recorded. Surveys conducted were modules of satisfaction with facial appearance, satisfaction with cheeks, satisfaction with skin, psychological function, social function, aging appearance appraisal, and satisfaction with the outcome.	The mean age of the 14 patients included in this study was 44.9-11.9 y (range: 33-65 y) and all were women	NR	A combination of PRP and micro-fat grafting with soft harvesting and processing can be viewed as a useful surgical technique to restore volume and enhance skin quality in facial soft tissue augmentation. Minimal damage during harvesting the fat graft, appropriate processing, and the addition of PRP in combination with the fat graft may increase patient and surgeon satisfaction related to outcomes.	N.R
Cárdenas ²⁷ (2006), USA, English	Case series	By comparison with preoperative and postoperative control photographs	From 1 to 36 mo (average, 15 mo).	78 rhinoplasties were performed, with injection of autologous fat. Of the 78 patients, 61 were primary rhinoplasties and 17 were secondary rhinoplasties	There were no complications with this procedure such as infection, hematoma, or bleeding from the donor site nor was there any infection in the nasal dorsum. We did not observe any minor irregularities, and the aspect and quality of the skin improved in all of the patients. A total of 77 patients were satisfied with the procedure. One patient was dissatisfied but for reasons unrelated to the lipoinjection procedure.	71 were women and 7 were men between the ages of 14 and 56 y.	The subcutaneous tissue of the inner knee (the fat was placed in the radix, dorsum sides, and supratip region, with the amount determined according to the case)	Fat injection into the nose as a refinement of rhinoplasty is a fast, easy, inexpensive procedure for obtaining regular and smooth contours on the nasal dorsum that lasts over time. Adipose tissue is an ideal origin of transplantation cells for augmentation of soft tissues because it is abundant, easy to obtain in large quantities, and safe to harvest. Because adipose tissue is an ideal source of stem cell tissue, the injection of fat tissue can increase the concentration of mesenchymal stem cells in the recipient tissue. Its application at regular intervals during adulthood can maintain volume and elasticity wherever it is applied.	Adipose tissue is an ideal origin of transplantation cells for augmentation of soft tissues because it is safe to harvest

Table 2. Continued

First author (y), country of origin, language	Study type	Measurement	Mean follow-up (range)	Number of cases (primary/secondary)	Complication/satisfaction	Mean age / sex	Fat harvesting site	Overall efficacy	Relative safety
Yukse ²⁸ (2012), USA, English	Case series	Case series	8 wk	59 primary rhinoplasty cases. In 12 cases, "external nasal fat grafting" (without dissection) was the only component of the rhinoplasty, while in 47 cases it was part of the rhinoplasty in addition to cartilage grafting and other steps.	Complications were evaluated: Tip Excess: 3 (due to vertical shift) Supratip fullness: 4 (due to vertical shift) Inadequate height: 3 (required additional grafting) in 59 cases.	NR	NR	Nasal augmentation can be achieved in primary rhinoplasty cases. Volume shift due to the gravity may occur in some cases, and the use of PRP and extended external stabilizing pressure can be utilized to prevent this. Fat grafting can play a significant role in primary rhinoplasty cases and delivers the advantage of minimized dissection and improved skin quality due to the preadipocyte contribution. It can be utilized solely in limited number of cases.	N.R
Maia ²⁹ (2019), NY, English	Case series	Reviewed preoperative and postoperative images	The mean follow-up was 3 y.	22 patients (all primary)	The majority of patients reported a high degree of satisfaction. No complications were observed.	Age, 15–19 y	Fat was harvested from flanks (most common donor site) and inferior abdomen	The combination of rhinoplasty and autologous fat grafting offers very satisfactory aesthetic outcomes and improvement of facial balance with minimal added time, cost, and risk.	Autologous fat grafting is a simple, repeatable, and safe alternative method to correct volumetric deficiencies in the face.
Lin ³⁰ (2017), Taiwan.	Case series	Preoperative and postoperative 3D photography images.	3 mo	13 consecutive patients (all primary)	Serious complications, such as retinal artery occlusion and stroke, have been reported in the literature as a result of arterial injection of synthetic fillers or autologous fat graft.	12 women and 1 man. The mean age of the patient was 34.03 ± 7.28 y (range: 22–47 y)	The lower abdomen	Different anatomical recipient sites may have different graft retention rates; a graft retention rate of 44.54% (range: 21%–74%) was reported (Figs. 8–11); knowledge of the expected graft retention rate for each recipient site is valuable, which allows the clinicians to better inform the patients and to determine if serial injections are necessary. The mean retention rate was 44.54% (range: 21%–74%).	The procedure will be more safe considering the following safety measures during fat injection of the nose is that: 1) providing vasoconstriction and decreasing the chance of arterial injection by the use of epinephrine 2) applying finger pressure to compress the lumen of angular artery during injection. The finger pressure is lifted only after the injection is completed.

Table 2. Continued

First author (y), country of origin, language	Study type	Measurement	Mean follow-up (range)	Number of cases (primary/secondary)	Complication/satisfaction	Mean age / sex	Fat harvesting site	Overall efficacy	Relative safety
Huang (2015) USA, English	A prospective study	The McNemar-Bowker test (time vs nasal tip sensation) was used to detect statistical significance.	The follow-up period was weeks 2, 4, 8, and 12.	30 Patients (all primary)	None of the patients was noted to have any complications during the postoperative period. Postoperative numbness occurs in most of the patients receiving nasal microfat injections. Partial to complete recovery of nasal tip sensation can be expected to occur over a 3-mo period. ($P < 0.05$). The percentage of those experiencing paresthesia after the microfat injections also gradually diminished to none.	Young women (age 20.04 - 3.63 y)	The abdomen	Using less invasive techniques, however, the variation in the long-term outcomes regarding transplanted volume loss has been reported. The loss and recovery of nasal tip sensation after microfat grafting were quantified. It is known that the nasal tip, along with other areas, is the most susceptible part of the body	N.R

FG, fat grafting; MAFT, microautologous fat transplantation; Mo, month; NR, not reported; Y, year.

significant fat harvesting site morbidities, and does not trigger an immune response.^{35,36} Various synthetic or autologous grafts have been used for improving the nasal contour and correcting various deformations. Among them, alloplastic materials such as the nonbiodegradable fillers are long-lasting and have a much longer duration of efficacy than autologous grafts such as autologous fat grafts. Foreign body reaction and its consequences are one of the most common complications in alloplastic materials. In case of serious complications, complex removal surgery might be needed, which sometimes contributes to further complications, such as cerebrospinal fluid leakage, surgical scar, shortnose deformity, and the remaining unsatisfactory aesthetic results.²³ Fat grafting offers several benefits over such synthetic fillers; it improves the skin quality at the recipient site and body contour at the harvesting site (mostly abdomen or thigh) without causing immunogenicity and foreign body reaction. Likewise, fat injection is a cost-benefit treatment option.³⁷

More than half of our included materials reported on patient satisfaction with aesthetic results of fat injection. The satisfaction rates were mostly high and ranged from 63% to 100%.

In most of our included materials, no complication was reported for peri/postoperative period.^{3,21,22,24,26,27,29,30,32} Although, some papers reported manageable complications such as an insufficient volume or decreased volume by resorption,²⁸ tip excess and supratip fullness,²⁸ and mild displacement.²⁵ A common unpleasant finding in

most of the patients receiving lipofilling is experiencing postsurgical numbness/paresthesia, which is expected to recover partially or completely over the first 3 months postoperative period and gradually diminish to none.³²

Although rare, there are several reports of serious, even mortal, complications after augmentation rhinoplasty with fat grafting. The ophthalmic artery occlusion is an ocular complication after autologous fat injection. The acute pressure increase caused by the forceful fat injection into the injected site artery might force a fat embolus to travel to the ophthalmic artery.³⁸

There was a report of mortal sepsis after augmentation rhinoplasty using silicone implant and fat grafting. Due to the anatomical features of the septal mucosa (rich blood supply), infection might easily spread to the brain. Aggressive treatment is the best strategy to prevent sepsis in such cases.³⁹ Therefore, clinicians should give particular attention to inform patients regarding the potential adverse effects of fat grafting. In order to have a safe injection and to minimize the potential complications:

1. Safety measures should be advocated to lower the risk of arterial cannulization. For instance, the lumen of the angular artery should be compressed using finger pressure, and fat delivery be done while withdrawing from the recipient site. likewise, sharp needles should be avoided.⁴⁰
2. Generating excessive pressure while injecting fat should be avoided; therefore, the use of a ratcheting gun is not proper for this purpose.³⁰

Table 3. The Risk of Bias Assessment for Included Studies

First author (year)	1	2	3	4	5	6	7	8	Overall appraisal
Kornstein ²¹ (2015)	Y	Y	Y	N	N	Y	Y	Y	6/8
Xu ²³ (2019)	Y	Y	Y	Y	N	Y	Y	Y	7/8
Gabrick ²⁴ (2019)	Y	Y	Y	Y	N	Y	Y	Y	7/8
Cárdenas ²⁷ (2007)	Y	Y	Y	Y	N	N	Y	Y	6/8
Monreal ²⁵ (2011)	Y	Y	Y	Y	N	Y	Y	Y	7/8
Kao ³³ (2016)	N	Y	N	N	N	Y	Y	Y	4/8
Ozer ²⁶ (2019)	Y	Y	Y	Y	N	Y	Y	Y	7/8
Yukse ²⁸ (2012)	N	Y	Y	Y	N	Y	N	Y	5/8
Maia ²⁹ (2019)	Y	Y	Y	Y	N	Y	Y	Y	7/8
Lin ³⁰ (2017)	N	Y	Y	Y	N	Y	N	Y	5/8
Huang ³² (2015)	Y	Y	Y	Y	N	Y	N	Y	6/8
Baptista ²² (2013)	Y	Y	Y	Y	N	N	Y	Y	6/8

N, no; Y, yes.

Fat Graft Retention Rate and the Need for Fat Injection Touch-Up Process

To date, the main critic of lipofilling is the unpredictability of long-term retention. Two types of variables affect the long-term retention rate: intrinsic patient-related variables, such as age, status, and location of the recipient site,⁴¹ accompanying additional surgical procedures, and extrinsic variables, such as fat harvesting, processing, and delivery techniques.^{30,31} Only the latter group is controllable. In order to achieve the desired aesthetic results, repeating the injection for some cases seemed to be necessary.²⁸ Lin et al reported that a further fat injection is necessary after 1 year in 23% of the cases. Some preserve the excess fat using cryopreservation for further series of fat injection (if needed).⁷ Although, the overcorrection by injecting the excess fat under pressure is not advised especially for sites with minimal skin laxity such as the dorsum as it might result in irregular resorption and necrosis.³⁰

Limitations and Strengths

This systematic review was not flawless. First, only a small number of published papers were found on the use of fat injection for nasal aesthetic correction. Second, the included materials were all case series and retrospective reviews with various follow-up times and no control group, which made the meta-analysis not viable. Case series mostly suffer low internal validity because of lacking comparator groups exposed to the same variables; although, reporting similar outcomes might increase their total value.

Another limitation was the language of the included studies. We excluded languages other than English, which might cause some levels of detection bias and missing parts of literature regarding the topic.

The follow-ups had a range of 2 weeks to 5.2 years. The wide range makes it difficult to draw any final conclusion on injectable fat grafts. Due to the limited number of included papers, considering papers with follow-up beyond 6 months was not possible.

Nonetheless, to our knowledge, no systematic review has assessed the clinical outcome of fat injection for nasal correction. Future studies with larger sample sizes and long-term follow-ups on complications and retention rate are warranted.

CONCLUSIONS

Autologous fat injection is an effective and minimally invasive treatment for nasal aesthetic and contour correction with a high satisfaction rate and low complication rate. Although clinical expertise is essential to have a safe injection and to minimize the potential complications, preserving the excess fat for further fat injection (if needed) is recommended.

Disclosures

The authors declared no potential conflicts of interest with respect to the research, authorship, and publication of this article.

Funding

The authors received no financial support for the research, authorship, and publication of this article.

REFERENCES

- Johnson ON 3rd, Kontis TC. Nonsurgical rhinoplasty. *Facial Plast Surg*. 2016;32(5):500-506.
- Erol OO. Injection of compressed diced cartilage in the correction of secondary and primary rhinoplasty: a new technique with 12 years' experience. *Plast Reconstr Surg*. 2017;140(5):673e-685e.
- Kao WP, Lin YN, Lin TY, et al. Microautologous fat transplantation for primary augmentation rhinoplasty: long-term monitoring of 198 Asian patients. *Aesthet Surg J*. 2016;36(6):648-656.
- Simonacci F, Bertozzi N, Grieco MP, Grignaffini E, Raposio E. Procedure, applications, and outcomes of autologous fat grafting. *Ann Med Surg (Lond)*. 2017;20:49-60.
- Talbot SG, Parrett BM, Yaremchuk MJ. Sepsis after autologous fat grafting. *Plast Reconstr Surg*. 2010;126(4):162e-164e.
- Lazzeri D, Agostini T, Figus M, Nardi M, Pantaloni M, Lazzeri S. Blindness following cosmetic injections of the face. *Plast Reconstr Surg*. 2012;129(4):995-1012.
- Jie L, Xiaoning Y, Xin L, et al. Clinical study of rhinoplasty with autologous rib cartilage and facial fat grafting to rebuild facial balance. *J Tissue Eng Reconstr Surg*. 15(1):32.
- Nguyen PS, Baptista C, Casanova D, Bardot J, Magalon G. [Autologous fat grafting and rhinoplasty]. *Ann Chir Plast Esthet*. 2014;59(6):548-554.
- Yan Z, Wang G-M, Hu Y, Zhuo T. Augmentation rhinoplasty by autologous fat grafting [J]. *Chin J Aesthet Med*. 2010;12:985-994.
- Chen J-J, Wu Y-J, Lu J-L, et al. The application of autologous fat granules injection in augmentation rhinoplasty. *Chin J Aesthet Med*. 2013;v.5(2):2.
- Na D-S, Jung S-W, Kook K-S, Lee Y-H. Augmentation rhinoplasty with dermofat graft & fat injection. *Arch Plast Surg*. 2011;38(1):53-62.
- Lo S, Sinrachtanant C. Immediate autologous fat graft augmentation rhinoplasty after removal of extruding or infected silicone implant. *Clin Otolaryngol*. 2012;37(4):333-334.
- Kim YK. Orbital fat pad for nasal tip augmentation in far Eastern rhinoplasty. In: *Advanced Aesthetic Rhinoplasty*. Springer; 2013:745-752.
- Piotet E, Beguin C, Broome M, et al. Rhinopharyngeal autologous fat injection for treatment of velopharyngeal insufficiency in patients with cleft palate. *Eur Arch Otorhinolaryngol*. 2015;272(5):1277-1285.
- Erdogan B, Tuncel A, Adanali G, Deren O, Ayhan M. Augmentation rhinoplasty with dermal graft and review of the literature. *Plast Reconstr Surg*. 2003;111(6):2060-2068.
- Nakakita N, Sezaki K, Yamazaki Y, Uchinuma E. Augmentation rhinoplasty using an L-shaped auricular cartilage framework combined with dermal fat graft for cleft lip nose. *Aesthetic Plast Surg*. 1999;23(2):107-112.
- Bektas G, Cinpolat A, Rizvanovic Z. Nasal filling in plastic surgery practice: primary nasal filling, nasal filling for post-rhinoplasty defects, rhinoplasty after hyaluronidase injection in dissatisfied nasal filling patients. *Aesthetic Plast Surg*. 2020;44(6):2208-2218.
- Sterodimas A. Stromal enriched lipograft for rhinoplasty refinement. *Aesthet Surg J*. 2013;33(4):612-614.
- Ciloglu S, Duran A, Yigit AK, Buyukdogan H, Keskin E. Keutel syndrome: augmentation of the nose with serial fat grafting. *Ann Maxillofac Surg*. 2015;5(2):287-288.
- Murad MH, Sultan S, Haffar S, Bazerbachi F. Methodological quality and synthesis of case series and case reports. *BMJ Evid Based Med*. 2018;23(2):60-63.
- Kornstein AN, Nikfarjam JS. Fat grafting to the forehead/ glabella/radix complex and pyriform aperture: aesthetic and anti-aging implications. *Plast Reconstr Surg Glob Open*. 2015;3(8):e500.
- Baptista C, Nguyen PS, Desouches C, Magalon G, Bardot J, Casanova D. Correction of sequelae of rhinoplasty by lipofilling. *J Plast Reconstr Aesthet Surg*. 2013;66(6):805-811.
- Xu J, Jiang B, Shen Y. Effectiveness of autologous fat grafting in scaring after augmentation rhinoplasty. *J Craniofac Surg*. 2019;30(3):914-917.
- Gabrick K, Walker M, Timberlake A, Chouairi F, Saberski E, Steinbacher D. The effect of autologous fat grafting on edema and ecchymoses in primary open rhinoplasty. *Aesthet Surg J*. 2020;40(4):359-366.
- Monreal J. Fat grafting to the nose: personal experience with 36 patients. *Aesthetic Plast Surg*. 2011;35(5):916-922.
- Ozer K, Colak O. Micro-autologous fat transplantation combined with platelet-rich plasma for facial filling and regeneration: a clinical perspective in the shadow of evidence-based medicine. *J Craniofac Surg*. 2019;30(3):672-677.
- Cárdenas JC, Carvajal J. Refinement of rhinoplasty with lipoinjection. *Aesthetic Plast Surg*. 2007;31(5):501-505.
- Yuksel E, Spira M, Yazgan H. Role of fat grafting in primary rhinoplasty. *Plast Reconstr Surg*. 2012;130(5S-1):44-45.
- Maia M, Lukash FN. Autologous fat grafting in young patients: a simple and effective way to achieve facial balance. *Ann Plast Surg*. 2019;83(3):253-257.
- Lin S, Hsiao YC, Huang JJ, et al. Minimal invasive rhinoplasty: fat injection for nasal dorsum contouring. *Ann Plast Surg*. 2017;78(3 Suppl 2):S117-S123.
- Gerth DJ, King B, Rabach L, Glasgold RA, Glasgold MJ. Long-term volumetric retention of autologous fat grafting processed with closed-membrane filtration. *Aesthet Surg J*. 2014;34(7):985-994.
- Huang L. Does sensation return to the nasal tip after microfat grafting? *J Oral Maxillofac Surg*. 2015;73(7):1396.e1-6.
- Gabrick K, Gary C, Saberski E, et al. Autologous fat grafting's role in primary rhinoplasty. *Plast Reconstr Surg Glob Open*. 2018;6(9 Suppl):90-99.

34. Clauser L, Zavan B, Galiè M, Di Vittorio L, Gardin C, Bianchi AE. Autologous fat transfer for facial augmentation: surgery and regeneration. *J Craniofac Surg*. 2019;30(3):682-685.
35. Coleman SR. Structural fat grafts: the ideal filler? *Clin Plast Surg*. 2001;28(1):111-119.
36. Erol OO. Microfat grafting in nasal surgery. *Aesthet Surg J*. 2014;34(5):671-686.
37. Mojallal A, Lequeux C, Shipkov C, et al. Improvement of skin quality after fat grafting: clinical observation and an animal study. *Plast Reconstr Surg*. 2009;124(3):765-774.
38. Xing L, Almeida DR, Belliveau MJ, et al. Ophthalmic artery occlusion secondary to fat emboli after cosmetic nasal injection of autologous fat. *Retina*. 2012;32(10):2175-2176.
39. Kim MH, Baik BS, Yang WS, Ha W, Ji SY. Sepsis leading to mortality after augmentation rhinoplasty with a septal extension graft and fat grafting. *Arch Plast Surg*. 2016;43(3):295-296.
40. Coleman SR. Avoidance of arterial occlusion from injection of soft tissue fillers. *Aesthet Surg J*. 2002;22(6):555-557.
41. Mojallal A, Shipkov C, Braye F, Breton P, Foyatier JL. Influence of the recipient site on the outcomes of fat grafting in facial reconstructive surgery. *Plast Reconstr Surg*. 2009;124(2):471-483.