



Brown fat necrosis with calcifications in the newborn: Risk factors, radiographic findings, and clinical course

Eleza T. Golden, *Children's Healthcare of Atlanta*
[Paula Dickson](#), *Emory University*
[Stephen Simoneaux](#), *Emory University*

Journal Title: Indian Journal of Radiology and Imaging

Volume: Volume 28, Number 1

Publisher: Thieme | 2018-01-01, Pages 107-110

Type of Work: Article | Final Publisher PDF

Publisher DOI: 10.4103/ijri.IJRI_67_17

Permanent URL: <https://pid.emory.edu/ark:/25593/vk1pw>

Final published version: http://dx.doi.org/10.4103/ijri.IJRI_67_17

Copyright information:

© 2018 Indian Journal of Radiology and Imaging Published by Wolters Kluwer - Medknow.

This is an Open Access work distributed under the terms of the Creative Commons Attribution-NonCommercial-ShareAlike 4.0 International License (<https://creativecommons.org/licenses/by-nc-sa/4.0/>).

Accessed January 22, 2022 12:46 PM EST

Brown fat necrosis with calcifications in the newborn: Risk factors, radiographic findings, and clinical course

Eleza T Golden, Paula Dickson, Stephen Simoneaux

Department of Radiology and Imaging Sciences, Children’s Healthcare of Atlanta and Emory University, 1405 Clifton Road NE, Atlanta, Georgia 30322

Correspondence: Dr. Eleza Golden, M.D., Northside Radiology Associates 5775 Glendridge Dr #525 Atlanta, GA 30328.
E-mail: egolden@northsideradiology.com

Abstract

Objective: To describe the radiographic appearance of subclinical calcified brown fat necrosis and the associated clinical and laboratory findings. **Materials and Methods:** Picture Archiving and Communications System (PACS) was searched using keywords “soft tissue calcification” and “chest.” The clinical record was searched for prior cardiac surgery, bypass, Extracorporeal Membrane Oxygenation (ECMO) and prostaglandin use. Age when calcifications were first detected, location, resolution, and associated laboratory abnormalities were recorded. **Results:** Nine patients were identified. None had skin lesions. All patients had congenital heart disease and had experienced cardiac/respiratory arrest and/or severe hypotension 1–6 weeks before soft tissue calcifications occurred. Calcifications resolved by 9 weeks to 5 months in 3 patients. The remaining were either deceased or lacked follow-up imaging. Renal ultrasound was performed in all but 1 patient. Nephrocalcinosis was only seen in 1 patient. **Conclusion:** Brown fat necrosis is subclinical, diagnosed on plain film, and likely self-limited. It occurs in term and preterm infants who have undergone significant systemic stress and carries a poor prognosis.

Key words: Neonate; neonatal imaging; subcutaneous fat necrosis

Introduction

Brown fat is responsible for the maintenance of body temperature and is prone to ischemia.^[1-3] It was reported in 5.5% of 400 perinatal autopsies with 13% occurring in infants with congenital heart disease.^[3] Typically seen in term infants, it can occur in preterm infants.^[2,4-9] Neonatal risk factors include meconium aspiration, macrosomia, hypoxic ischemic encephalopathy with or without cooling, and congenital heart disease. Maternal risk factors include diabetes, hypertension, preeclampsia, seizure, thyroid dysfunction, and illicit drug use.^[2,5,8-12] Larger case series

included patients with visible findings on physical exam^[10] and were not specific to infants with congenital heart disease. Prior studies in infants with subclinical findings and congenital heart disease only included 1–2 patients treated with prostaglandins.^[2,8,9] To our knowledge, this is the first large case series of infants with subclinical brown fat necrosis and congenital heart disease.

Materials and Methods

Due to the noninvasive nature of the study, it did not necessitate IRB approval according to our institution’s

This is an open access journal, and articles are distributed under the terms of the Creative Commons Attribution-NonCommercial-ShareAlike 4.0 License, which allows others to remix, tweak, and build upon the work non-commercially, as long as appropriate credit is given and the new creations are licensed under the identical terms.

For reprints contact: reprints@medknow.com

Cite this article as: Golden ET, Dickson P, Simoneaux S. Brown fat necrosis with calcifications in the newborn: Risk factors, radiographic findings, and clinical course. *Indian J Radiol Imaging* 2018;28:107-10.

Access this article online	
<p>Quick Response Code:</p> 	<p>Website: www.ijri.org</p> <p>DOI: 10.4103/ijri.IJRI_67_17</p>

policies. PACS was searched using the keywords “soft tissue calcification” and “chest” and 9 patients were identified. The clinical record was searched for history of cardiac surgery, bypass, extracorporeal membrane oxygenation (ECMO), prostaglandin use, hypoxia, age when calcifications were first detected, location, resolution, and associated hypercalcemia, thrombocytopenia, and elevated triglycerides. Renal ultrasound results were evaluated for nephrocalcinosis or other renal abnormality. Eight of our patients had neurologic imaging with cranial ultrasound, and two were abnormal. If available, follow-up radiographs were evaluated to document evolution and/or resolution of soft tissue calcification. Imaging was reviewed by two pediatric radiologists and a pediatric radiology fellow.

Results

Nine patients were identified, 4 males and 5 females. Of the 9 patients, 6 infants were premature and 3 were full-term. The average gestational age was 35 weeks, the median 36 weeks, and the range was 26–39 weeks. None of the patients had skin lesions on exam. All patients had underlying congenital heart disease and experienced cardiac and/or respiratory arrest and/or severe hypotension between 1 and 6 weeks before soft tissue calcifications were detected by radiography. The mean age at which soft tissue calcifications appeared was 4 weeks, the median age was also 4 weeks, with a range of 2–8 weeks.

Single ventricle physiology was the most common lesion occurring in 6 patients (67%) (1 tricuspid atresia, 1 double outlet right ventricle, and 4 hypoplastic left heart syndrome). Of the remaining 3 patients, one had trisomy 18 with a large ventricular septal defect (VSD), patent ductus arteriosus (PDA), and bicuspid aortic and pulmonic valves. Another had heterotaxy with complete atrioventricular (AV) canal, and the last patient had a PDA and patent foramen ovale (PFO). Just over half (56%) received prostaglandin therapy. Seven (78%) patients underwent cardiac surgery whereas 5 (56%) required bypass and/or ECMO. All patients had some form of cardiac or respiratory failure and/or severe hypotension. Only 2 (22%) patients underwent cooling.

Soft tissue calcifications occurred bilaterally in all patients in areas of brown fat in the cervical, supraclavicular, and periscapular soft tissues and axilla. In 1 patient, calcifications were notably asymmetric with increased prominence on the right relative to the left [Figure 1].

The remaining 8 patients demonstrated relatively symmetric soft tissue calcification. Three of the patients had follow-up imaging which documented resolution by 9 weeks to 5 months [Figures 2 and 3].

Hypercalcemia was present in 4 (44%), thrombocytopenia in 7 (78%), and elevated triglycerides in 8 (89%). Renal

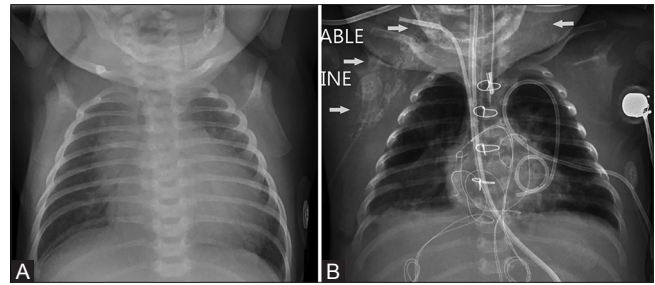


Figure 1 (A and B): Ex full term infant with hypoplastic left heart syndrome who was on bypass during surgical repair followed by ECMO for low cardiac output shortly after surgery. The patient was deceased at the time this study was conducted. Chest radiograph at 8 days of life (A) notable for absence of soft tissue calcifications and at 7 weeks old (B) with marked asymmetric right greater than left axillary, periscapular, and peri-clavicular calcifications as indicated by white arrows

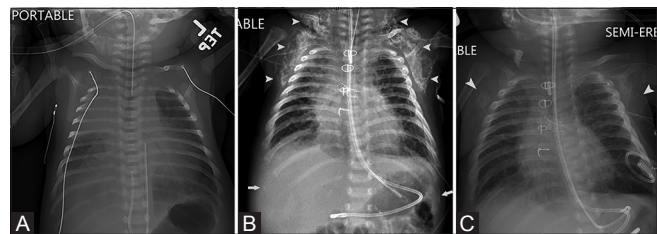


Figure 2 (A-C): Ex full term infant with hypoplastic left heart syndrome who underwent a stage I Norwood procedure and Sano right ventricle to pulmonary artery shunt at 1 week of age followed a little over a week later by acute decompensation requiring pressor support, large right pneumothorax and thoracotomy with chest exploration and large right hemothorax evacuation. Chest radiograph at 4 days old (A) demonstrates absence of soft tissue calcifications. Chest radiograph at 10 weeks (B) demonstrates significant bilateral soft tissue calcifications in the bilateral axillae, peri-scapular, peri-clavicular regions (white arrowheads) as well as the bilateral upper quadrants of the abdomen as indicated by white arrows. Chest radiograph at 3 months (C) demonstrates near complete interval resolution of soft tissue calcifications (white arrowheads)

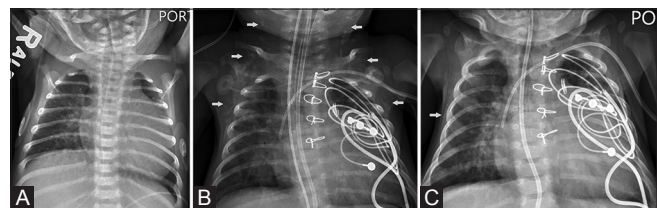


Figure 3 (A-C): Ex full term infant with double-outlet right ventricle, heterotaxy syndrome with polysplenia who underwent PDA ligation, pulmonary artery banding, and epicardial pacemaker placement. Severe bradycardia and hypotension episode preceded appearance of soft tissue calcification by 3-4 weeks. Chest radiograph at 4 days old (A) demonstrates absence of soft tissue calcifications. Chest radiograph at 6 weeks (B) demonstrates significant bilateral soft tissue calcifications in the bilateral axillae, peri-scapular, peri-clavicular regions (white arrows). Chest radiograph at 9 weeks (C) demonstrates near complete interval resolution of soft tissue calcifications

ultrasound was performed in all but 1 patient, and only a single patient had findings of nephrocalcinosis. Eight patients had cranial ultrasounds. Six were normal whereas 1 patient developed hydrocephalus and a second patient who was a 26-week premature infant developed bilateral germinal matrix hemorrhages. No brain magnetic resonance

imaging (MRI) was performed in our patient population. At the time of this study, 4 (44%) of the patients were deceased.

Discussion

In keeping with prior studies,^[2,8,9] our case series reaffirms that brown fat necrosis is subclinical, diagnosed on plain film, and in a third of our patients, appeared self-limited. This is in contradistinction to the clinically apparent subcutaneous fat necrosis of newborns that presents with erythematous plaques and nodules typically occurring over areas of bony protuberance such as the occipital scalp, face, neck, back, and upper extremities.^[5,10,12] Moreover, the distribution of subcutaneous fat necrosis seen on plain radiograph differs from the clinical entity and primarily occurred around the shoulder in the axilla and surrounding the scapula and clavicle in our study population.

When radiographic subcutaneous fat necrosis is identified, further laboratory and imaging work up may be prudent and should be suggested by the radiologist. Similar to other studies, several patients demonstrated mild hypercalcemia and thrombocytopenia, and almost all had elevated triglycerides.^[4-6] As other studies have suggested that severe hypercalcemia can occur up to 6 months of age,^[4-6,11] radiologists can help identify patients that need to be followed up long term. Nephrocalcinosis has previously been reported in patients with brown fat necrosis.^[4-6] All our patients had renal ultrasound with one demonstrating nephrocalcinosis. Therefore, it may be wise for the radiologist to suggest further evaluation with renal ultrasound if soft tissue calcifications are identified on radiographs. Moreover, as there have been over 20 studies in the literature describing subcutaneous fat necrosis in infants with hypoxic ischemic encephalopathy with or without cooling, screening neurologic imaging should be considered including screening head ultrasound or MRI brain depending on the level of clinical suspicion.^[12] In our study, 2 (25%) out of 8 patients imaged demonstrated abnormalities on cranial ultrasound, which emphasizes the importance of neurologic imaging if subcutaneous fat calcifications are identified.

While brown fat necrosis has previously been described in term infants with congenital heart disease treated with prostaglandins,^[2,8,9] two-third of the patients in our case series were premature and 4 (44%) did not receive prostaglandins.

However, all our patients had significant underlying cardiac disease with single ventricle physiology in the majority. Of note, of the 7 patients who underwent cardiac surgery, 5 had significant postoperative complications. Specifically, 3 patients had hemodynamic decompensation within the first 48 hours following surgery requiring ECMO. Further,

3 patients had a postoperative course complicated by significant hemorrhage including compressive mediastinal hematoma, large right hemothorax, and large gastric bleed all of which required operative management. While 2 patients did not experience significant hemorrhage, both had severe hypotensive shock. Thus, rather than medication related, brown fat necrosis may be a result of profound hypoperfusion and hypoxic/ischemic insult regardless of gestational age, prostaglandin use, or cardiac surgery. Finally, 1 patient's postoperative course was complicated by wound dehiscence and acute respiratory failure approximately 2 weeks later. Moreover, given that 4 of 9 patients were deceased at the time this study was conducted, we propose that the presence of soft tissue calcification is a marker of significant ischemic injury and should be considered a poor prognostic indicator. This finding is in keeping with prior case reports of 3 infants with congenital heart disease treated with prostaglandins all of which died as described by Raboi *et al.*, Miller *et al.*, and Herman *et al.*

Conclusion

Brown fat necrosis is subclinical, diagnosed on plain film, and likely self-limited. It may be a marker of prior systemic stress. It has previously been described in term infants with congenital heart disease treated with prostaglandins. Rather than medication related, it may be related to hypoxic/ischemic insult and occurs in both term and premature infants with underlying cardiac disease who experience cardiac or respiratory arrest with hypotension. Similar to other studies, several patients demonstrated mild hypercalcemia, thrombocytopenia, and nearly all had elevated triglycerides. However, other studies have suggested that severe hypercalcemia can occur up to 6 months of age and the radiologist can help identify patients that need to be followed. Additionally, renal ultrasound should be considered to evaluate for nephrocalcinosis.

Financial support and sponsorship

Nil.


Conflicts of interest

There are no conflicts of interest.

References

1. Aherne W, Hull D. Brown adipose tissue and heat production in the newborn infant. *The J Pathol Bacteriol* 1966;91:223-34.
2. Miller SF. Resolution of calcific brown fat necrosis associated with prostaglandin therapy for cyanotic congenital heart disease in neonates: Report of two cases. *Pediatr Radiol* 2004;34:919-23.
3. Stephenson TJ, Variend S. Visceral brown fat necrosis in postperinatal mortality. *J Clin Pathol* 1987;40:896-900.
4. Akin MA, Akin L, Sarici D, Yilmaz I, Balkanli S, Kurtoglu S. Follow-up during early infancy of newborns diagnosed

- with subcutaneous fat necrosis. *J Clin Res Pediatr Endocrinol* 2011;3:216-8.
5. Akcay A, Akar M, Oncel Y, Kizilelema A, Erdevi O, Oguz SS, *et al.* Hypercalcemia Due to Subcutaneous Fat Necrosis in a Newborn After Total Body Cooling. *Pediatr Dermatol* 2013;30:120-3.
 6. Shumer DE, Thaker V, Taylor GA, Wassner AJ. Severe hypercalcemia due to subcutaneous fat necrosis: Presentation, management, and complications. *Arch Dis Child Fetal Neonatal Ed* 2014;99:F419-21.
 7. Mitra S, Dove J, Somisetty SK. Subcutaneous fat necrosis in newborn-an unusual case and review of literature. *Eur J Pediatr* 2011;170:1107-10.
 8. Raboi CA, Smith W. Brown fat necrosis in the setting of congenital heart disease and prostaglandin e1 use: A case report. *Pediatr Radiol* 1999;29:61-3.
 9. Herman TE, Siegel MJ. Special imaging casebook. hypoplastic left heart, prostaglandin therapy gastric focal foveolar hyperplasia and brown fat necrosis. *J Perinatol* 2001;21:263-5.
 10. Burden AD, Krafchik BR. Subcutaneous fat necrosis of the newborn: A review of 11 cases. *Pediatr Dermatol* 1999;16:384-7.
 11. Dudnik J, Walther FJ, Beekman RP. Subcutaneous fat necrosis of the newborn: Hypercalcemia with hepatic and atrial myocardial calcification. *Arch Dis Child Fetal Neonatal Ed* 2003;88:F343-5.
 12. Grass B, Weiel L, Hagmann C, Brotschi B. Subcutaneous fat necrosis in neonates with hypoxic ischaemic encephalopathy registered in the swiss national asphyxia and cooling register. *BMC Pediatr* 2015;15:73.



Copyright of Indian Journal of Radiology & Imaging is the property of Wolters Kluwer India Pvt Ltd