

Published in final edited form as:

*Am J Med Genet A*. 2011 July ; 0(7): 1605–1615. doi:10.1002/ajmg.a.34043.

## Genomic Characterization of Prenatally Detected Chromosomal Structural Abnormalities Using Oligonucleotide Array Comparative Genomic Hybridization

Peining Li<sup>1,\*</sup>, Pawel Pomianowski<sup>1</sup>, Miriam S. DiMaio<sup>1</sup>, Joanne R. Florio<sup>1</sup>, Michael R. Rossi<sup>1,2</sup>, Bixia Xiang<sup>1,3</sup>, Fang Xu<sup>1</sup>, Hui Yang<sup>1</sup>, Qian Geng<sup>1,4</sup>, Jiansheng Xie<sup>4</sup>, and Maurice J. Mahoney<sup>1</sup>

<sup>1</sup>Department of Genetics, Yale University School of Medicine, New Haven, Connecticut

<sup>2</sup>Department of Human Genetics, Emory University School of Medicine, Atlanta, Georgia

<sup>3</sup>Department of Cytogenetics, City of Hope, Duarte, Connecticut

<sup>4</sup>Shenzhen Maternity and Child Healthcare Hospital, Shenzhen, Guangdong, China

### Abstract

Detection of chromosomal structural abnormalities using conventional cytogenetic methods poses a challenge for prenatal genetic counseling due to unpredictable clinical outcomes and risk of recurrence. Of the 1,726 prenatal cases in a 3-year period, we performed oligonucleotide array comparative genomic hybridization (aCGH) analysis on 11 cases detected with various structural chromosomal abnormalities. In nine cases, genomic aberrations and gene contents involving a 3p distal deletion, a marker chromosome from chromosome 4, a derivative chromosome 5 from a 5p/7q translocation, a de novo distal 6q deletion, a recombinant chromosome 8 comprised of an 8p duplication and an 8q deletion, an extra derivative chromosome 9 from an 8p/9q translocation, mosaicism for chromosome 12q with added material of initially unknown origin, an unbalanced 13q/15q rearrangement, and a distal 18q duplication and deletion were delineated. An absence of pathogenic copy number changes was noted in one case with a de novo 11q/14q translocation and in another with a familial insertion of 21q into a 19q. Genomic characterization of the structural abnormalities aided in the prediction of clinical outcomes. These results demonstrated the value of aCGH analysis in prenatal cases with subtle or complex chromosomal rearrangements. Furthermore, a retrospective analysis of clinical indications of our prenatal cases showed that approximately 20% of them had abnormal ultrasound findings and should be considered as high risk pregnancies for a combined chromosome and aCGH analysis.

### Keywords

prenatal diagnosis; chromosomal structural abnormalities; genomic imbalances; array comparative genomic hybridization (aCGH)

### INTRODUCTION

Cytogenetic analyses using rapid fluorescence in situ hybridization (FISH) screening for targeted chromosomal aneuploidy on inter-phase cells and conventional Giemsa-band (G-

band) karyotyping on metaphase cells have been the standard procedures for prenatal diagnosis of chromosomal abnormalities. This approach is effective in detecting aneuploidy and large chromosomal rearrangements but has significant limitations in characterizing supernumerary marker chromosomes, derivative or recombinant chromosomes from familial or de novo balanced rearrangements, subtle imbalances and complex chromosomal abnormalities. Interpretation of clinical outcomes from these latter abnormalities remains a challenge for prenatal genetic counseling. Current practice compares the observed abnormalities with published cases with the same or similar aberrations. However, these cases are often rare or unique, and the abnormalities designated by conventional chromosome G-band patterns lack the resolution to assess the involved genomic content. These limitations hinder the inference of karyotype-phenotype predictions and the identification of candidate genes associated with fetal anomalies.

For the past 5 years, validated whole genome aCGH analysis has been applied to the clinical diagnosis of chromosomal abnormalities and genomic aberrations of pediatric patients with mental retardation and developmental delay (MR/DD) [Cheung et al., 2005; De Vries et al., 2005; Shaffer et al., 2007; Xiang et al., 2008]. A recent multi-center comparison among Agilent's whole genome oligonucleotide array users showed significantly improved analytical resolution and abnormal detection rate compared to routine metaphase analysis [Xiang et al., 2010]. Experience gained from the pediatric population has led to the extension of this genomic approach to prenatal diagnosis [Lu et al., 2008]. Recently, two systematic evaluations of whole genome microarray analyses of 182 and 300 prenatal specimens, respectively, demonstrated the technical feasibility and clinical validity of aCGH testing for prenatal diagnosis [Coppinger et al., 2009; Van den Veyver et al., 2009]. In this study, we present results of whole genome aCGH analysis on 11 prenatal cases with various chromosomal structural abnormalities. Genomic imbalances and involved gene contents were delineated in nine cases and genetic counseling was conducted with information about the genomic characteristics for all these chromosomal abnormalities. The results indicate that aCGH is a useful tool for delineating compound and subtle chromosomal abnormalities and should be an integral part of prenatal diagnosis.

## MATERIALS AND METHODS

### Case Selection

From 2007 to 2009, the Yale cytogenetics laboratory performed karyotype analysis on 681 amniotic fluid (AF) specimens and 1,045 chorionic villus (CV) samples. In this group of samples, there were 176 cases (10.2%) with numerical chromosomal abnormalities and 33 cases (1.9%) with various chromosomal structural abnormalities. To evaluate the incidence of various chromosomal abnormalities in different prenatal clinical indications, we further classified numerical chromosomal abnormalities into: (a) trisomy 21, (b) other numerical abnormalities involving the sex chromosomes, all autosomes (except chromosome 21) and polyploids, and (c) mosaic numerical abnormalities. Structural abnormalities were also classified into: (a) unbalanced structural abnormalities, (b) apparently balanced structural rearrangements including translocations and inversions, and (c) mosaic structural abnormalities. Indications for prenatal diagnosis were first categorized based on the maternal age and then a single indication using the following priority order: (1) abnormal ultrasound findings; (2) abnormal first or second trimester maternal serum screening; and (3) family history. As shown in Table I, of these 209 cases with abnormal chromosomal findings, 176 (84.2%) had numerical abnormalities and 33 (15.8%) showed various structural rearrangements. Of these latter 33 cases, 13 cases had an inherited balanced Robertsonian translocation, inversion, or reciprocal translocation, 3 cases showed mosaicism for a structural abnormality, and 6 cases lacked follow-up parental samples; these 22 cases were excluded from aCGH analysis. The remaining 11 cases included subtelomeric

deletions, a marker chromosome, additional material of unknown origin, derivative or recombinant chromosomes from familial carriers with balanced rearrangements, and suspected unbalanced rearrangements. Further genomic analysis using aCGH was done on these cases (Table II).

### Chromosome G-Banding and FISH Analysis

Chromosome analysis was performed on G-band metaphases prepared from cultured AF and CV cells or cultured peripheral blood lymphocytes according to the laboratory's standard protocols. Twenty metaphases were analyzed for each sample. FISH was performed using selected ToTelVysion™ subtelomeric probes and locus-specific probes (Vysis/Abbott, Abbott Park, IL). FISH using labeled RPCI-11 BAC clones 33M11 at 4q35.2, 696J7 at 5q21.1, 826F19 at 12q24.33, 1152O8 at 21q21.3, and 347B5 at 21q22.13 (Roswell Park Cancer Institute, Buffalo, NY) as probes was performed as previously described [Li et al., 2006].

### Oligonucleotide Array Comparative Genomic Hybridization (aCGH)

Genomic DNA was extracted from cultured AF or CV cells, or peripheral blood lymphocytes using the Genra Puregene Kit (Qiagen, Valencia, CA). The DNA concentration was measured using a NanoDrop spectrophotometer (Thermo Fisher Scientific, Inc., Waltham, MA) and high molecular weight DNA was verified by agarose gel electrophoresis. For each sample, 3 µg of genomic DNA was used following the manufacturer's protocol for the Agilent Human Genome CGH microarray 44K kit (~44,000 70-mer oligonucleotides) and 180K kit (~180,000 70-mer oligonucleotides) (Agilent Technologies, Inc., Santa Clara, CA). This aCGH procedure can achieve 99% sensitivity and 99% specificity using a sliding window of five to seven contiguous oligonucleotides, indicating an analytical resolution of 300–500 kilobase (kb) for the 44K platform and 100–150 kb for the 180K platform [Xiang et al, 2008]. The base pair designations of 44K and 180K aCGH were based on the May 2004 Assembly (NCBI35/hg17) and the March 2006 Assembly (NCBI36/hg18) of the UCSC Human Genome browser (<http://genome.ucsc.edu/>), respectively.

## RESULTS

The prenatal clinical assessment, chromosomal analysis and aCGH results and available postnatal findings of the 11 cases are summarized in Table II. The de novo 11q/14q translocation (Case 7) and the paternally inherited 21q insertion into a 19q (Case 11) did not have copy number changes in or around the breakpoint regions by aCGH, which indicated balanced rearrangements within the analytical resolution. Genomic imbalances were found in the remaining nine cases. The detailed clinical findings and cytogenomic results were described as follows. To protect patient privacy, some information of family structure or history was omitted, and important biological information has been retained.

### Case 1

CV sampling was performed because of advanced maternal age (AMA). Chromosome analysis detected a 3p deletion. Analysis of the parents' chromosomes showed the mother to be a carrier of the same deletion. Further analysis using aCGH noted an identical 9.3 megabase (Mb) deletion of 3p26.3–p25.3 (Chr3:48,714–9,332,435) including genes from *CHL1* to *SRGAP3* in the fetus and the mother. The mother had an unremarkable medical and family history. The baby was born at term and had a normal pediatric examination in the newborn period.

## Case 2

Aminocentesis was performed because of AMA and abnormal first trimester screening results with increased risks for Down syndrome and trisomy 18. Chromosome analysis of amniocytes detected a mosaic pattern of a supernumerary marker in 70% of metaphase cells. Peripheral blood karyotypes for both parents were normal. Further aCGH analysis of DNA from cultured amniocytes revealed a mosaic 18.6 Mb duplication of 4p13–q13.1 (Chr4:44,026,548–62, 632,708) including genes from *KCTD8* to *LPHN3*. FISH analysis using a centromeric probe for chromosome 4 showed positive hybridization signals on the marker chromosome and the presence of this marker in 95% of lymphocytes after delivery. The term newborn had a normal length and weight, and growth and development were normal at 1 year. There were no dysmorphic findings.

## Case 3

Amniocentesis was performed because of abnormal ultrasound findings noted at 22 weeks of gestation. The findings included cerebellar hypoplasia, dilation of part of the lateral ventricles, interruption of the aortic arch, aplasia of the ascending aorta, persistent left superior vena cava, ventricular septal defect, thymic hypoplasia, and a horseshoe kidney. Chromosome analysis performed on cultured amniocytes was suspicious for a 5p deletion, and aCGH revealed a 24.9 Mb deletion of 5p13.33–p14.1 (Chr5:78,942–24,977,357) and a 13.3 Mb duplication of 7q35–q36.3 (Chr7:143,495,352–158,781,538). FISH analysis using sub-telomeric probes for chromosomes 5 and 7 confirmed the absence of 5pter signal and the presence of 7qter signal in the derivative chromosome 5. Parental karyotyping found that the father of the pregnancy is a carrier for an apparently balanced translocation between chromosomal bands 5p14.1 and 7q35. The patient elected pregnancy termination.

## Case 4

Amniocentesis was performed at 29 weeks gestation because of abnormal ultrasound findings. At 22 weeks gestation, the fetus had mild enlargement of the right lateral cerebral ventricle (measurement 13 mm; normal range <10 mm) and the cerebellum measured slightly smaller than expected for gestational age. At 29 weeks gestation, there was bilateral cerebral ventriculomegaly (measuring 20–22 mm, normal range <10 mm). The serum AFP concentration determined at 18 weeks gestation was slightly elevated at 2.0 multiples of the medium (MoM). Chromosome analysis of cultured amniocytes revealed a deletion at 6q27 and FISH analysis using the subtelomeric 6qter probe confirmed the deletion. Concurrent aCGH analysis characterized this deletion as a 4.9 Mb deletion at 6q27 (Chr6:165,927,396–170,809,934) including genes from *PDE10A* to *PDCD2*. Parental chromosome analysis showed normal results. At 33 weeks gestation, the baby was delivered by cesarean after preterm premature rupture of membranes complicated by chorioamnionitis. Apgar scores were 8 and 9 at 1 and 5 min, respectively. The infant was transferred to the newborn intensive care unit due to ventriculomegaly and her abnormal karyotype and developed transient tachypnea of the newborn and metabolic acidosis. On day 21 she was medically stable for discharge.

## Case 5

Amniocentesis was performed because of AMA and an elevated MSAFP (2.7 MoM). Ultrasonographic evaluation at 18 weeks gestation demonstrated a unilateral right-sided cleft lip and suspected micrognathia. The karyotype of cultured amniocytes revealed a recombinant chromosome 8 resulting from a pericentric inversion of a chromosome 8 found to be present in the father, and aCGH defined a 28.3 Mb duplication of 8p23.3–p21.1 (Chr8:181,530–28,441,283) and a 0.8 Mb deletion at 8q24.3 (Chr8:145,464,363–146,250,824) (Fig. 1). The duplication includes genes from *ZNF596* to *FZD3* and the

deletion contains genes from *BOP1* to *TMED10P*. The patient elected to terminate this pregnancy.

### Case 6

A woman with a history of recurrent spontaneous abortions (SAB) had abnormal ultrasound findings at 18 weeks of gestation which included a cystic structure in the posterior fossa with complete absence of the cerebellar vermis consistent with a Dandy–Walker malformation, “strawberry-shaped” head with a flattened occiput, micrognathia, abnormal position of the hand with overlapping digits, levorotated cardiac axis with thickened tricuspid valve, enlarged right atrium, and a small ventricular septal defect. Amniocentesis detected an abnormal karyotype with a gain of a derivative chromosome 9 from a translocation between chromosomal bands 8p11.21 and 9q13. Parental chromosome analysis showed that the mother has an apparently balanced translocation between chromosomal bands 8p11.21 and 9q13. At 28 weeks of gestation, the patient presented in active labor and delivered a viable infant with Apgar scores of 6 and 8 at 1 and 5 min, respectively. Follow-up aCGH analysis performed on DNA extracted from the infant’s peripheral blood revealed a 42.6 Mb duplication of 8p23.3–p11.21 (Chr8:181,530–42,866,112) corresponding to genes from *ZNF596* to *RNF170* and a 40 Mb duplication of 9p24.3–p13.1 (Chr9:204,367–40,238,102) including genes from *C9orf66* to *CNTNAP3*. On physical examination, the infant had a brisk capillary refill with notable acrocyanosis, spinal defect with a mass and a tuft of hair over the sacrum, single palmar creases, hypoplastic nails of the hands and shaped pupils, low-set and posteriorly rotated ears, and micrognathia. The infant had progressive respiratory failure and died on the second day of life. An autopsy was not performed.

### Case 7

A woman was referred due to AMA. Chromosome analysis of cultured cells from the CV sample revealed a female complement with an apparently balanced translocation between 11q21 and 14q31. Concurrent aCGH study performed on DNA obtained from the CV sample and chromosome analysis on blood lymphocytes from the parents were normal. The infant was normal at full term birth and showed normal growth and development at age 3 years.

### Case 8

CV sampling was performed due to family history of Down syndrome. Analyses of cultured CV cells detected true mosaicism (level III) for additional material of unknown origin onto the distal long arm of a chromosome 12. Subsequent aCGH performed on DNA obtained from CV cells noted a 6.3 Mb segmental trisomy of 4q35.2 (Chr4:184,187,538–190,490,075), contiguous 0.9 Mb segmental tetrasomy (Chr5:99,486,385–100,401,951), and 2.8 Mb segmental trisomy (Chr5:100,678,690–103,437,734) of 5q21.1 and a 6.6 Mb segmental trisomy of 12q24.32–q33 (Chr12:125,761,905–132,378,336). FISH tests using dual color BAC clone probes 33M11 (4q35.2) and 696J7 (5q21.1) as well as a single probe 826F19 (12q24.33) observed three signals for each probe in 40 and 45 nuclei out of the 50 interphase cells scored, respectively; examination of metaphase cells noted two signals for the 33M11 and 696J7 probes on the targeted loci of 15 metaphases, and duplicated signals of the 826F19 probe on a 12q in 12 out of the 15 metaphases (Fig. 2, Table II). The aCGH observed duplications of 4q35 and 5q21.1 were noted in the interphase cells but not seen in the metaphase chromosomes by FISH analysis; low mitotic activity of cells with these duplications from in vitro cell culture is a likely explanation. The patient elected to terminate this pregnancy.

### Case 9

A woman was referred due to AMA and a previous pregnancy of a trisomy 21 fetus. Sonography at 18 weeks showed measurements that lagged by 5–16 days from expected. Amniocentesis was performed and revealed a male complement with an unbalanced 13q/15q translocation missing the 13q33 dark band. FISH analysis using subtelomeric probes for 13qter and 15qter observed the 13qter signal on the derivative chromosome15 and the 15qter signal on the derivative chromosome 13. Subsequent aCGH analysis on DNA extracted from cultured amniocytes detected a 13.1 Mb deletion of 13q33.1–q34 (Chr13:100,838,094–114,077,122) including genes from *ITGBL1* to *CDC16* (Fig. 3A). The FISH and aCGH results confirmed the unbalanced translocation. Parental chromosome analysis showed normal results. The baby was delivered at 36 weeks gestation and his weight, length, and head circumference were at or below the 3rd centile. He required respiratory support within the first 24 hr of life. Physical exam showed hypospadias, right undescended testis, and anterior position of an imperforate anus. Brain MRI and echocardiography in the newborn period were normal. At a follow-up of age 27 months, he had visual impairment, seizure disorders, problems with balance and coordination, and neurogenic bladder.

### Case 10

A woman's fetus had a single umbilical artery at 20 weeks gestation with otherwise normal anatomy. Polyhydramnios developed in the third trimester and an amniocentesis was performed at 30 weeks. Chromosomal analysis noted additional material of unknown origin on 18q23; and aCGH defined a 23.9 Mb duplication of 18q12.3–q22.1 (Chr18:40,535,628–63,364,951) containing sequences from the *SETBP1* gene to the *CDH19* gene and a 12.5 Mb deletion of 18q22.1–q23 (Chr18:63,549,666–76,083,117) containing sequences from the *TMX3* gene to the *PARD6G* gene (Fig. 3B). Parental chromosome analyses were normal. The baby was delivered at 37 weeks of gestation and had several apneic episodes in the first 2 days of life. Dysmorphic features included a small misshaped left ear, hypertrophied gingivae including cysts, a vaginal tag, and plagiocephaly. Neurologically, the infant was hypotonic with an absent grasp reflex. An echocardiogram showed the presence of two ventricular and two atrial septal defects and protective pulmonary stenosis. Brain imaging showed deficient opercularization of the Sylvian fissures and incomplete folding of the hippocampuses. She died at 11 months, having had chronic cardiorespiratory and renal problems and neurologic deficits.

### Case 11

A woman was referred due to prior family history of miscarriages. Her husband was a known carrier of an undefined structural rearrangement involving a 21q segment insertion into another chromosome. Her husband's brother, who died at age 20, had profound MR; and karyotyping performed two decades ago noted a 21q deletion. Chromosome analysis performed on the cultured CV cells as well as the father's peripheral blood detected a similar chromosomal rearrangement. FISH analysis on the fetal and the paternal metaphases using a probe for the *RUNX1* locus at 21q22 revealed absence of signal in a chromosome 21 and presence of signal in a chromosome 19q. Further FISH analysis using BAC clone probes 115208 (21q21.3, including the *APP* gene) and 347B5 (21q22.13, including the *TTC3* and *DSCR3* genes) found positive signals on both normal and derivative chromosomes 21, which indicated that the inserted segment is about 10 Mb of 21q21.3–q22.13 (Fig. 4). Concurrent aCGH performed on the fetus and the father found a normal result, indicating that the fetus inherited a balanced ins(19;21) from the father. The infant was a full term healthy baby at birth and had normal weight, length, and development at 7 months of age.

## DISCUSSION

The whole genome aCGH analysis detected no copy number aberrations in the de novo 11q/14q translocation of case 7 and the familial insertion of a 21q segment into 19q of case 11. An identical mother-to-fetus 3p distal deletion was noted in case 1. A recent report suggested that the *SRGAP3* gene is the major determinant of MR in distal 3p deletion syndrome [Shuib et al., 2009]. In our case 1, the carrier mother has a 9.3 Mb deletion at 3p25.3 including the entire *SRGAP3* gene and presents a normal phenotype. Two large subtelomeric 3p deletions (10.1 Mb of patient 2,586 and 10.6 Mb of patient 2,831) with no obvious phenotype are documented in the DECIPHER database (<https://decipher.sanger.ac.uk>). These results provide evidence of segmental haplosufficiency of this 3p subtelomeric region and infer that the critical region and candidate genes for 3p deletion syndrome are most likely proximal to the *SRGAP3* gene. Because the parent with the chromosomal abnormality in cases 1 and 11 is phenotypically normal, the identical abnormality in the fetus is unlikely to be associated with adverse effects on development, and the risk of birth defects or functional problems in the fetus is only slightly increased over the background risk. Discordant phenotypes have been reported in a familial case of 4q subtelomeric duplication (2.441 Mb) and deletion (12.651 Mb) [Rossi et al., 2009] and benign or variable phenotypes of familial unbalanced variants have also been reported in the literature [Barber, 2005; Filges et al., 2009]; therefore, there should be caution with the interpretation of familial cases.

Of the remaining eight cases, 14 copy number aberrations ranging from 0.8 to 42.6 Mb were detected, and the gene contents and chromosomal break points were delineated. The detected genomic imbalances facilitate the interpretation of observed chromosomal abnormalities and the prediction of associated clinical phenotypes through comparison with reported cases involving similar genomic findings. Nonetheless, it is important to recognize that clinical uncertainties will remain until many cases with detailed genomic information are reported. For example, cytogenetic and clinical comparisons of previously reported cases of supernumerary marker or ring chromosome 4 showed mild to severe mental retardation and dysmorphic and overgrowth features in some but not all affected persons and a correlation of the overgrowth phenotype with a dosage effect of the *IGFBP7* gene was speculated [Bonnet et al., 2006]. Developmental delay and postnatal overgrowth might be suspected in case 2 because the 18.6 Mb supernumerary marker derived from chromosome 4 resulted in a partial segmental trisomy of over 65 genes including the *IGFBP7* gene. The infant in our case has not shown any abnormality at age 1 year; and the trisomy segment is smaller than that reported by Bonnet et al. For case 3, the compound effect from the 24.9 Mb deletion of 5p encompassing critical regions of speech delay, cat-like cry, MR, and facial dysmorphism of Cri du Chat syndrome [Zhang et al., 2005] and the 13.3 Mb 7q duplication [Lehnen et al., 2009] predicts a severe phenotype. The 6q27 deletion in case 4 includes the smallest deleted region and the proposed candidate gene *TBP* for MR [Rooms et al., 2006]. The major genomic imbalance in our case 5 is the 28.3 Mb segmental trisomy of 8p23.3–p21. A girl with 15 Mb dup(8p) and 0.5 Mb del(8q) recombinant chromosome from maternal inv(8)(p22q24.3) was reported with MR, minor facial abnormalities and hepatic focal nodular hyperplasia [Tokutomi et al., 2007]. It is obvious that our case 5 involves an even larger duplication segment which predicts a more severe phenotype. Direct FISH analysis of meiotic segregation in spermatozoa from carriers of a pericentric inversion of chromosome 8 observed approximately 38% recombinant sperm once the size of the inverted segment represented over 60% of chromosome 8 [Caer et al., 2008]. This data suggest that the inv(8) carrier father has a significantly increased recurrence risk of a fetus with an unbalanced recombinant chromosome. In case 6, the 8p duplication is even larger than that in case 5 and the large 9p duplication includes critical regions for MR and speech

delay [Zou et al., 2009]; the double segmental trisomy likely explains the obvious prenatal anomalies and severe neonatal adverse effects.

The mosaic pattern and genomic imbalances of 4q, 5q, and 12q found in CV cells of case 8 made it difficult to interpret the effects on the fetus or predict the clinical outcome. Case 9 had an unbalanced 13q/15q rearrangement involving a 13.1 Mb deletion of 13q33.1–q34. Based on the updated phenotypic map of 13q21.1–13qter, this deletion is related to microcephaly, prominent columella, heteropia, microphthalmia, thumb hypoplasia, and anal atresia [Kirchhoff et al., 2009].

Case 10 had a concomitant distal 18q duplication of q12.3–q22.1 and deletion of q22.1–q23. Boghosian-Sell et al. [1994] studied six patients with partial duplication of chromosome 18 and identified two noncontiguous regions, 18q12.3–q22.1 and 18q22.3–q23, that may work in conjunction to produce an Edward syndrome (trisomy 18) like phenotype. The duplication of 18q12.3–q22.1 may be associated with more severe MR. A recent report on three adult siblings with a 12 Mb duplication of 18q21.31–q22.2 and a review of literature revealed different clinical manifestations ranging from mild to severe MR, clinodactyly, and mild facial dysmorphism [Ceccarini et al., 2007]. Genomic mapping of 18q deletion phenotypes defined critical regions of dysmyelination, growth hormone response failure, aural atresia, and kidney malformation within 18q22.3–q23 [Cody et al., 2009]. These reported cases provided insight into the possible clinical outcome from the distal 18q duplication and deletion of our case 10. The major findings in the newborn period noted in case 10 are mild dysmorphism, hypotonia, and cardiac defect. Similar distal concomitant duplication and deletion rearrangements have been noted in 8p, 4q, and other chromosomes; an U-type sister chromatid exchange mechanism and other mechanisms have been proposed to explain the recurrence of these rearrangements [Xiang et al., 2008; Rossi et al., 2009; Rowe et al., 2009].

Characterization of simple chromosomal and genomic deletions and duplications in pediatric patients has allowed accurate subtractive mapping of critical regions and candidate genes for genotype–phenotype correlations. As demonstrated in our cases 1, 2, 4, and 9, genomic characterization of prenatally detected chromosome abnormalities provides valuable information for genetic counselors to describe the gene contents and to make more accurate predictions about the clinical outcomes. However, for cases involving deletions and duplications of different chromosomal segments or complex rearrangements, phenotypic predictions are more problematic due to compound effects of gene dosage and genomic position. Systematic study of additional clinical cases of recurrent complex rearrangements will hopefully facilitate better understanding of genotype–phenotype correlations and mutagenesis mechanisms.

Case-oriented prenatal and follow-up postnatal genomic analyses have been used to further delineate prenatally detected chromosomal abnormalities [Baldwin et al., 2008; Lehnen et al., 2009; Rossi et al., 2009]. As demonstrated in this report, further characterization of gene copy number aberrations as opposed to chromosomal G-band abnormalities provides better predictive insight and, in turn, better patient management. The aCGH analysis should be applied to any case with recognized complex or subtle chromosomal abnormalities. Of the 1,726 AF or CV chromosome analyses performed in our laboratory from 2007 to 2009, 209 cases (12.1%) had chromosomal abnormalities. About 84% (176/209) of these chromosomal abnormalities were aneuploidies and polyploidies which had been detected effectively by the current cytogenetic method and the remaining 16% (33/209) were structural abnormalities (Table I). Excluding the simple familial cases, at least 30% (11 of the 33 cases in the present study) and likely over 50% (12 unbalanced and 5 mosaic structural abnormalities out of 33

cases in Table I) of the prenatally detected structural rearrangements, which accounts for approximately 1% of our prenatal cases, will require further genomic characterization.

The recent multi-center study of 1,499 consecutive cases of pediatric MR/DD cases detected pathogenic copy number aberrations in 177 cases (12%), and approximately 53% of those pathogenic imbalances were less than 5 Mb which could be missed by routine chromosome analysis [Xiang et al., 2010]. Genomic analysis of two large series of prenatal cases indicated that aCGH can enhance the analytic resolution and detect pathogenic genomic imbalances in 2–3% of the prenatal cases referred by AMA, abnormal ultrasound findings and family history [Coppinger et al., 2009; Van den Veyver et al., 2009]. However, considering the challenge of detecting many non-pathogenic copy number variants and of interpreting clinical heterogeneity for many emerging genomic disorders, Friedman [2009] recommended cautious application of aCGH analysis in high risk pregnancies. Based on our observations (Table I), chromosomal abnormalities have been detected in 13.6% of AF and 29.7% of CV screened with abnormal ultrasound findings, and 30% of AF and 49.2% of CV when there was both AMA and abnormal ultrasound result. Therefore, pregnancies with abnormal ultrasound findings (approximately 20% of AF and CV samples, 349/1,726) should be considered as high risk pregnancies, and a combined chromosome and aCGH genomic analysis could be recommended. An integrated cytogenomic approach for prenatal diagnosis should include (1) rapid aneuploid FISH screening and conventional karyotype performed following the current guidelines to detect numerical abnormalities, (2) subsequent aCGH analysis on cases detected with subtle and complex structural chromosomal abnormalities, (3) parallel karyotype and aCGH tests on high risk pregnancies involving fetal anomalies observed via ultrasound, and (4) concurrent analysis of the parents with abnormal prenatal findings to sort out familial or de novo events. As demonstrated from the pediatric experience, this approach will be expected to increase the detection rate of chromosomal and genomic imbalances in prenatal diagnosis.

## Acknowledgments

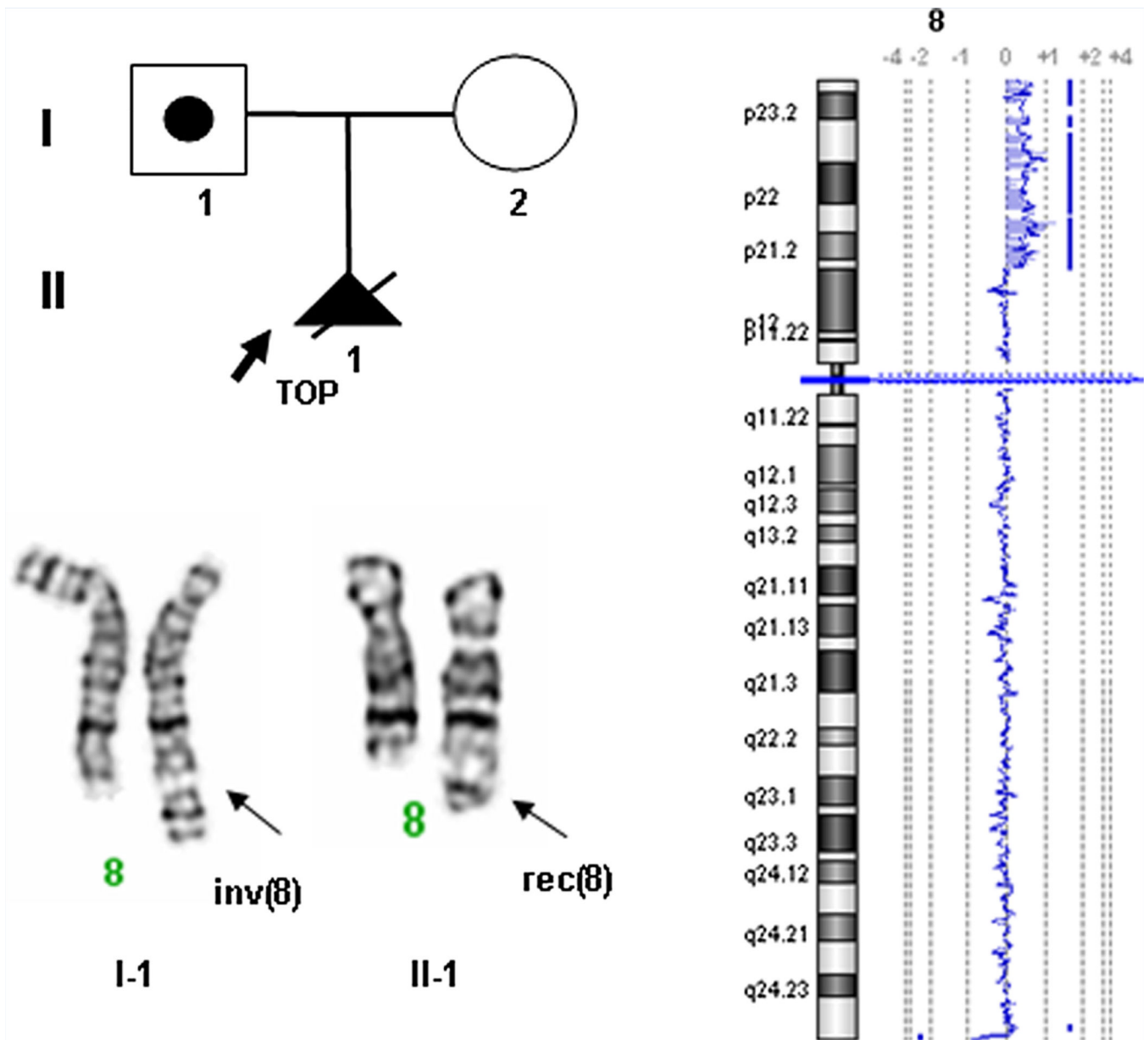
We would like to thank Joan Samuelson, Dongmei Wang, and Rachana Kumar for their technical support and helpful discussions, and also extend our appreciation to the patients and their family members who participated in this study. NIH training grant 5T32GM008753-09 to MRR supported part of this work.

## REFERENCES

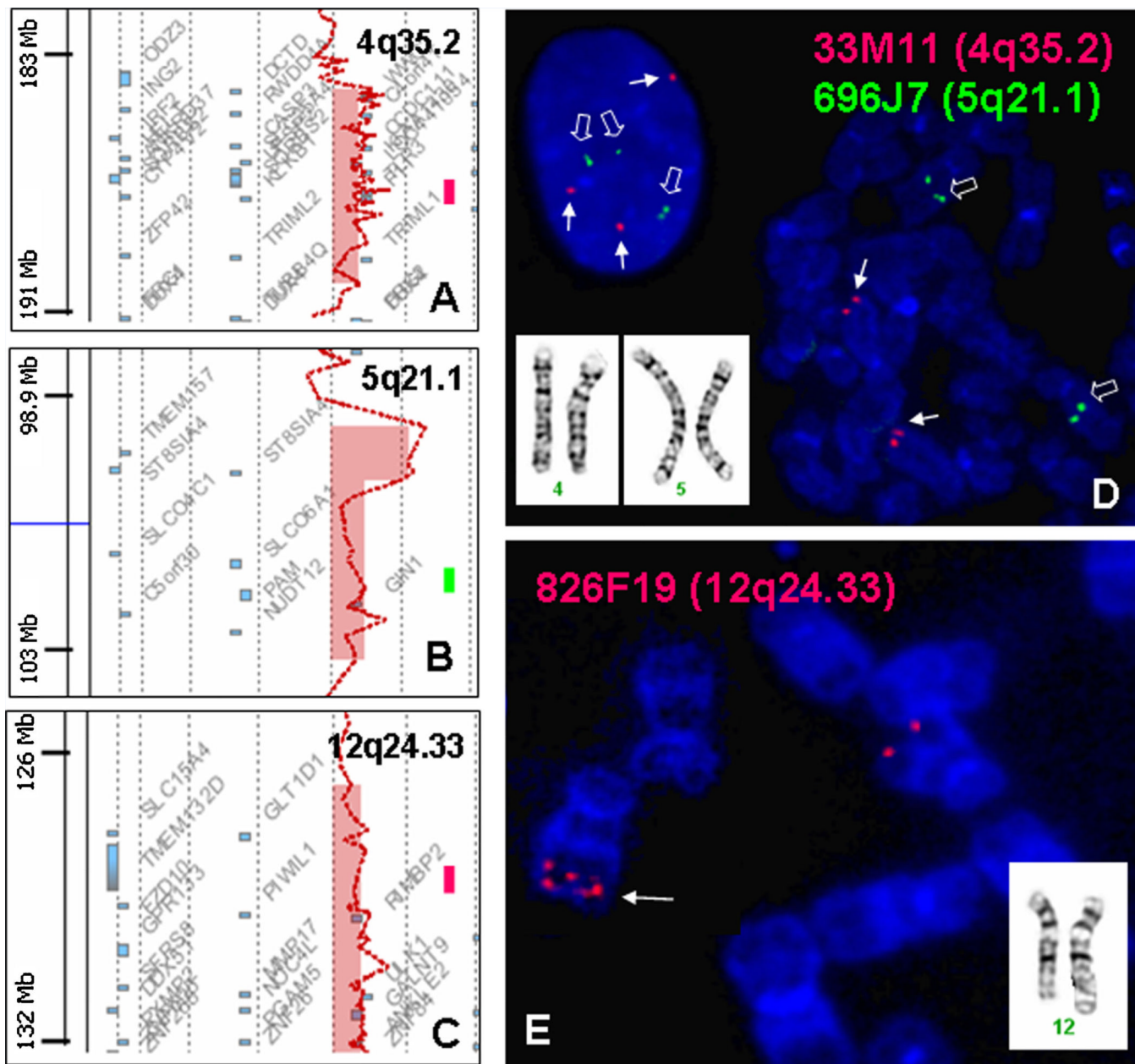
- Baldwin EL, May LF, Justice AN, Martin CL, Ledbetter DH. Mechanisms and consequences of small supernumerary marker chromosomes: From Barbara McClintock to modern genetic-counseling issues. *Am J Hum Genet.* 2008; 82:398–410. [PubMed: 18252220]
- Barber JCK. Directly transmitted unbalanced chromosome abnormalities and euchromatic variants. *J Med Genet.* 2005; 42:609–629. [PubMed: 16061560]
- Boghosian-Sell L, Mewar R, Harrison W, Shapiro RM, Zackai EH, Carey J, Davis-Keppen L, Hudgins L, Overhauser J. Molecular mapping of the Edwards syndrome phenotype to two noncontiguous regions on chromosome 18. *Am J Hum Genet.* 1994; 55:476–483. [PubMed: 8079991]
- Bonnet C, Zix C, Grégoire MJ, Brochet K, Duc M, Rousselet F, Philippe C, Jonveaux P. Characterization of mosaic supernumerary ring chromosomes by array-CGH: Segmental aneusomy for proximal 4q in a child with tall stature and obesity. *Am J Med Genet Part A.* 2006; 140A:233–237. [PubMed: 16411200]
- Caer E, Perrin A, Douet-Guilbert N, Amice V, De Braekeleer M, Morel F. Differing mechanisms of meiotic segregation in spermatozoa from three carriers of a pericentric inversion of chromosome 8. *Fertil Steril.* 2008; 89:1637–1640. [PubMed: 17603050]
- Ceccarini C, Sinibaldi L, Bernardini L, De Simone R, Mingarelli R, Novelli A, Dallapiccola B. Duplication 18q21.31–q22.2. *Am J Med Genet Part A.* 2007; 143A:343–348. [PubMed: 17256793]

- Cheung SW, Shaw CA, Yu W, Li J, Ou Z, Patel A, Yatsenko SA, Cooper ML, Furman P, Stankiewicz P, Lupski JR, Chinault AC, Beaudet AL. Development and validation of aCGH microarray for clinical cytogenetic diagnosis. *Genet Med.* 2005; 7:422–432. [PubMed: 16024975]
- Cody JD, Heard PL, Crandall AC, Carter EM, Li J, Hardies LJ, Lancaster J, Perry B, Stratton RF, Sebold C, Schaub RL, Soileau B, Hill A, Hasi M, Fox PT, Hale DE. Narrowing critical regions and determining penetrance for selected 18q- phenotypes. *Am J Med Genet Part A.* 2009; 149A:1421–1430. [PubMed: 19533771]
- Coppinger J, Alliman S, Lamb AN, Torchia BS, Bejjani BA, Shaffer LG. Whole-genome microarray analysis in prenatal specimens identifies clinically significant chromosome alterations without increase in results of unclear significance compared to targeted microarray. *Prenat Diagn.* 2009; 29:1156–1166. [PubMed: 19795450]
- De Vries BB, Pfundt R, Leisink M, Koolen DA, Vissers LE, Janssen IM, Reijmersdal S, Nillesen WM, Huys EH, Leeuw N, Smeets D, Sijm EA, Feuth T, van Ravenswaaij-Arts CM, van Kessel AG, Schoenmakers EF, Brunner HG, Veltman JA. Diagnostic genome profiling in mental retardation. *Am J Hum Genet.* 2005; 77:606–616. [PubMed: 16175506]
- Filges I, Röthlisberger B, Noppen C, Boesch N, Wenzel F, Necker J, Binkert F, Huber AR, Heinemann K, Miny P. Familial 14.5 Mb interstitial deletion 13q21.1–13q21.33: Clinical and array-CGH study of a benign phenotype in a three-generation family. *Am J Med Genet Part A.* 2009; 149A:237–241. [PubMed: 19161139]
- Friedman JM. High-resolution array genomic hybridization in prenatal diagnosis. *Prenat Diagn.* 2009; 29:20–28. [PubMed: 19009552]
- Kirchhoff M, Bisgaard A-M, Stoeva R, Dimitrov B, Gillissen-Kaesbach G, Fryns J-P, Rose H, Grozdanova L, Ivanov I, Keymolen K, Fagerberg C, Tranebjaerg L, Skovby F, Stefanova M. Phenotype and 244k array-CGH characterization of chromosome 13q deletions: An update of the phenotypic map of 13q21.1-qter. *Am J Med Genet Part A.* 2009; 149A:894–905. [PubMed: 19363806]
- Lehnen H, Maiwald R, Neyzen S, Kohlhase J, Böhm D, Ritterbach J, Behrend C, Schwennicke G. Severe phenotype in a girl with partial tetrasomy 7, karyotype 46,XX, trp(7)(q35q36). *Cytogenet Genome Res.* 2009; 125:248–252. [PubMed: 19738385]
- Li P, Zhang H, Huff S, Nimmakayalu M, Qumsiyeh M, Yu JW, Szekely A, Xu T, Pober BR. Karyotype-phenotype insights from 11q14.1–q23.2 interstitial deletions: FZD4 haploinsufficiency and exudative vitreoretinopathy in a patient with a complex chromosome rearrangement. *Am J Med Genet Part A.* 2006; 140A:2721–2729. [PubMed: 17103440]
- Lu XY, Phung MT, Shaw CA, Pham K, Neil SE, Patel A, Sahoo T, Bacino CA, Stankiewicz P, Kang SH, Lalani S, Chinault AC, Lupski JR, Cheung SW, Beaud AL. Genomic imbalances in neonates with birth defects: High detection rates by using chromosomal microarray analysis. *Pediatrics.* 2008; 122:1310–1318. [PubMed: 19047251]
- Rooms L, Reyniers E, Scheers S, van Luijk R, Wauters J, Van Aerschoot L, Callaerts-Vegh Z, D’Hooge R, Mengus G, Davidson I, Courtens W, Kooy RF. TBP as a candidate gene for mental retardation in patients with subtelomeric 6q deletions. *Eur J Hum Genet.* 2006; 14:1090–1096. [PubMed: 16773126]
- Rossi MR, DiMaio M, Kaymakcalan H, Xiang B, Lu K, Mahoney MJ, Seashore G, Li P. Clinical and genomic characterization of distal duplications and deletions of chromosome 4q: Study of two cases and review of the literature. *Am J Med Genet Part A.* 2009; 149A:2788–2794. [PubMed: 19921640]
- Rowe LR, Lee JY, Rector L, Kaminsky EB, Brothman AR, Martin CL, South ST. U-type exchange is the most frequent mechanism for inverted duplication with terminal deletion rearrangements. *J Med Genet.* 2009; 46:694–702. [PubMed: 19293169]
- Shaffer LG, Beaudet AL, Brothman AR, Hirsch B, Levy B, Martin CL, Mascarello JT, Rao KW, et al. A working group of the laboratory quality assurance committee of the American College of Medical Genetics ACMG Standards and Guidelines: Microarray analysis for constitutional cytogenetic abnormalities. *Genet Med.* 2007; 9:654–662. [PubMed: 17873655]
- Shuib S, McMullan D, Rattenberry E, Barber RM, Rahman F, Zatyka M, Chapman C, Macdonald F, Latif F, Davison V, Maher ER. Micro-array based analysis of 3p25–p26 deletions (3p— syndrome). *Am J Med Genet Part A.* 2009; 149A:2099–2105. [PubMed: 19760623]

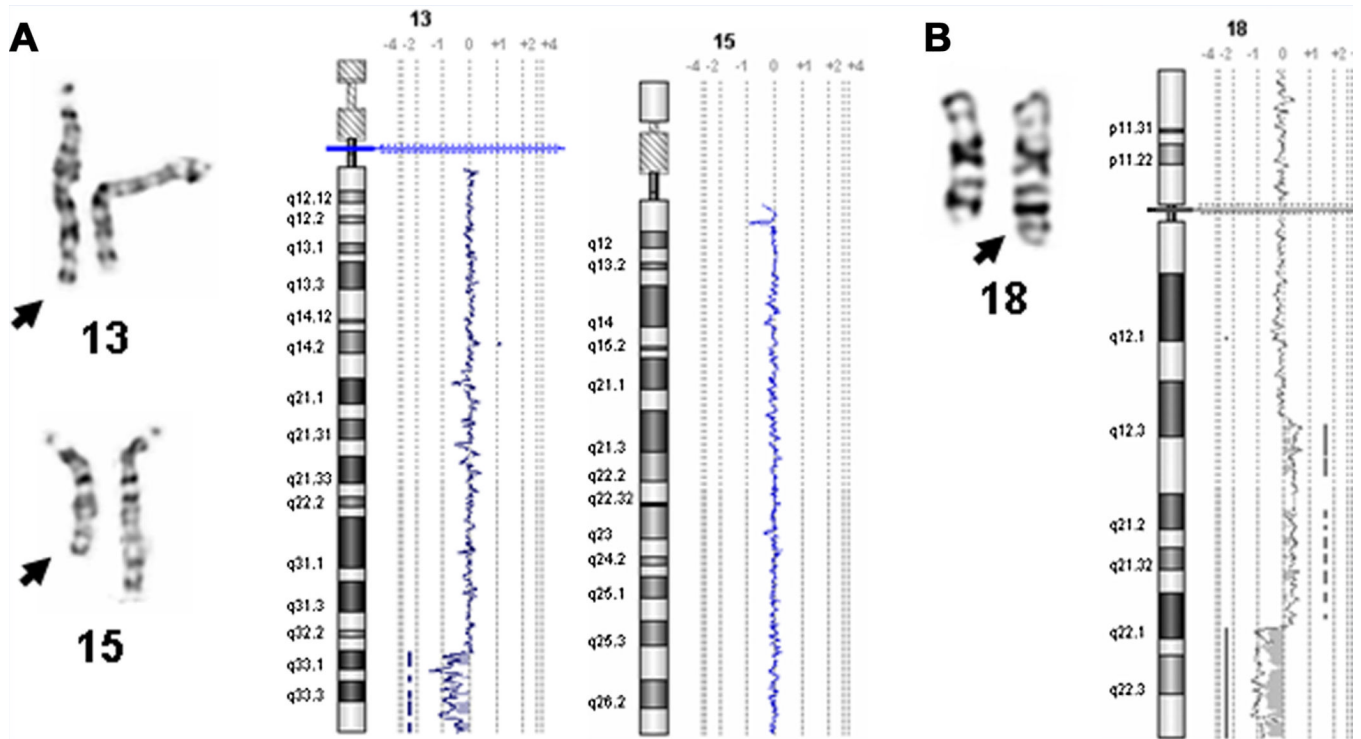
- Tokutomi T, Hayashi S, Imai K, Chida A, Ishiwata T, Asano Y, Inazawa J, Nonoyama S. Dup (8p)/del(8q) recombinant chromosome in a girl with hepatic focal nodular hyperplasia. *Am J Med Genet Part A*. 2007; 143A:1334–1337. [PubMed: 17506094]
- Van den Veyver IB, Patel A, Shaw CA, Pursley AN, Kang SH, Simovich MJ, Ward PA, Darilek S, Johnson A, Neill SE, Bi W, White LD, Eng CM, Lupski JR, Cheung SW, Beaud AL. Clinical use of array comparative genomic hybridization (aCGH) for prenatal diagnosis in 300 cases. *Prenat Diagn*. 2009; 29:29–39. [PubMed: 19012303]
- Xiang B, Li A, Valentin D, Novak N, Zhao HY, Li P. Analytical and clinical validity of whole genome oligonucleotide array comparative genomic hybridization for pediatric patients with mental retardation and developmental delay. *Am J Med Genet Part A*. 2008; 146A:1942–1954. [PubMed: 18627053]
- Xiang B, Zhu H, Shen Y, Miller D, Lu K, Hu X, Andersson HC, Narumanchi TM, Wang Y, Martinez JE, Wu BL, Li P, Li MM, Chen TJ, Fan YS. Genome-wide oligonucleotide array CGH for etiological diagnosis of mental retardation: A multi-center experience on 1,499 clinical cases. *J Mol Diagn*. 2010; 12:204–212. [PubMed: 20093387]
- Zhang X, Snijders A, Segraves R, Zhang X, Niebuhr A, Albertson D, Yang H, Gray J, Niebuhr E, Bolund L, Pinkel D. High-resolution mapping of genotype-phenotype relationships in cri du chat syndrome using array comparative genomic hybridization. *Am J Hum Genet*. 2005; 76:312–326. [PubMed: 15635506]
- Zou YS, Huang X-L, Ito M, Newton S, Milunsky JM. Further delineation of the critical region for the 9p-duplication syndrome. *Am J Med Genet Part A* v149A. 2009:272–276.



**FIG. 1.** Familial chromosome abnormalities characterized in case 5. Pedigree shows *inv(8)* in the father (I-1) and *rec(8)* with *dup(8p)* and *del(8q)* in the fetus (II-1) resulting from meiotic recombination; aCGH chromosome view shows the large 28.3 Mb duplication of 8p23.3–p21.1 and the subtle 0.8 Mb deletion at 8q24.3. [Color figure can be seen in the online version of this article, available at [http://onlinelibrary.wiley.com/journal/10.1002/\(ISSN\)1552-4833](http://onlinelibrary.wiley.com/journal/10.1002/(ISSN)1552-4833)]

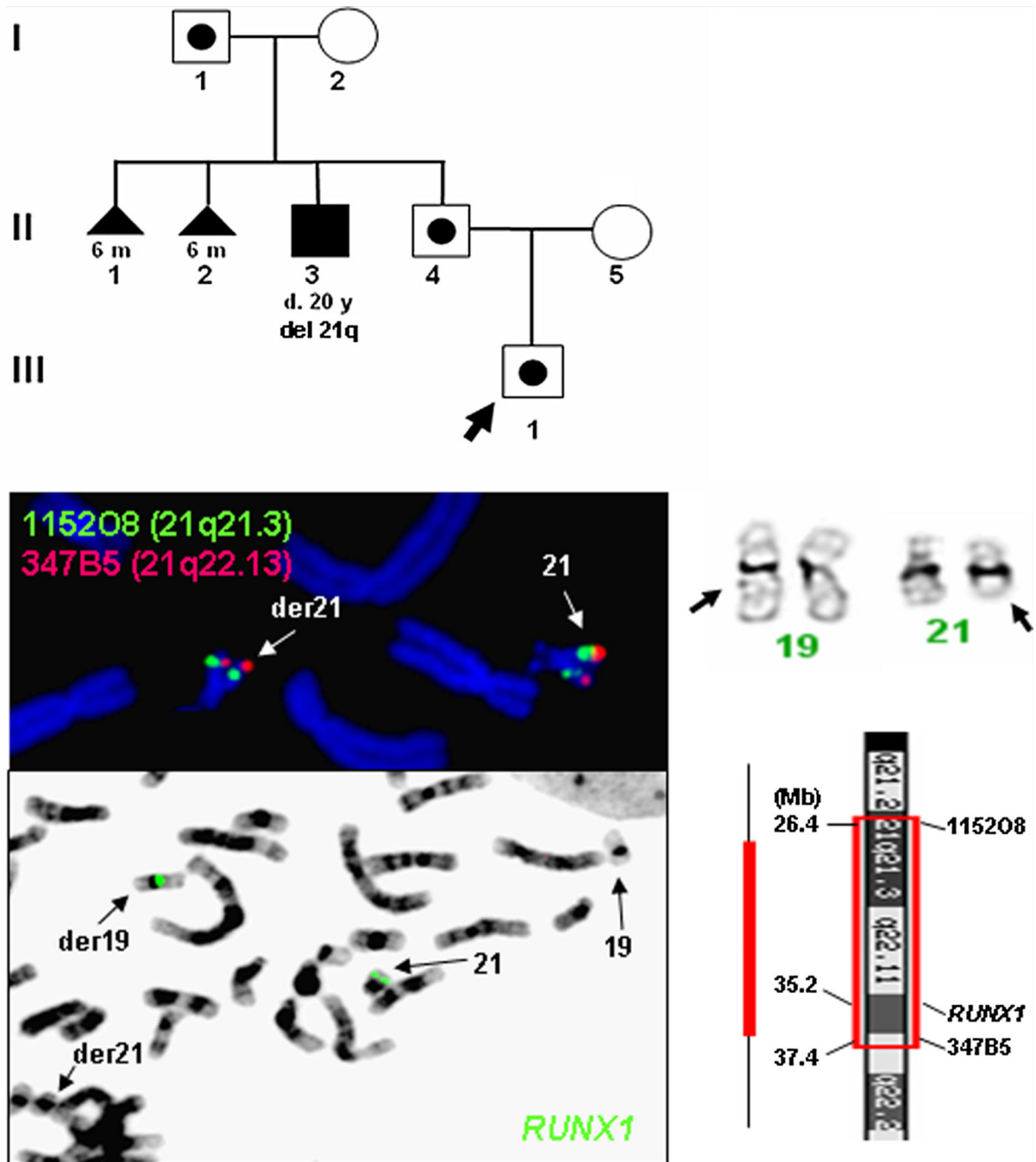


**FIG. 2.** Segmental duplications and triplication in case 8. A–C: aCGH gene views show a 6.3 Mb duplication of 4q35.2, a 0.9 Mb triplication and a 2.8 Mb duplication of 5q21.1, and a 6.6 Mb duplication at 12q24.32–q33 (color bar maps selected BAC clone location). D: FISH using probes for 33M11 (4q35.2, red, arrow) and 696J7 (5q21.1, green, thick arrow) shows three signals on an interphase and two signals on a metaphase (insets for chromosomes 4 and 5). E: FISH using probes for 826F19 (12q24.33, red) shows duplicated signals on a 12q (arrow; inset for chromosome 12). [Color figure can be seen in the online version of this article, available at [http://onlinelibrary.wiley.com/journal/10.1002/\(ISSN\) 1552-4833](http://onlinelibrary.wiley.com/journal/10.1002/(ISSN) 1552-4833)]



**FIG. 3.**

Genomic imbalances detected from de novo chromosomal abnormalities. A: aCGH reveals a 13.1 Mb deletion of 13q33.1–q34 from an unbalanced 13q/15q translocation (arrow) in case 9. B: aCGH defines a 23.9 Mb duplication of 18q12.3–q22.1 and a 12.5 Mb deletion of 18q22.1–q23 from the derivative chromosome 18 (arrow) in case 10. [Color figure can be seen in the online version of this article, available at [http://onlinelibrary.wiley.com/journal/10.1002/\(ISSN\)1552-4833](http://onlinelibrary.wiley.com/journal/10.1002/(ISSN)1552-4833)]



**FIG. 4.**

Familial chromosomal abnormality in case 11. Pedigree shows family history of multiple miscarriages. The paternal grandfather (I-1) is an obligate carrier and the fetus (proband III-1) and his father (II-4) have the same derivative chromosomes 19 and 21 (arrows). FISH image shows hybridization signals from labeled 115208 (green) and 347B5 (red) probes on the normal 21 and the derivative chromosome 21. Reversed DAPI FISH shows hybridized signals of *RUNX1* probe (green) on the derivative chromosome 19 and the normal 21. A diagram shows an estimated 10 Mb segment of 21q21.3–q22.13 insert into 19q. [Color figure can be seen in the online version of this article, available at [http://onlinelibrary.wiley.com/journal/10.1002/\(ISSN\)1552-4833](http://onlinelibrary.wiley.com/journal/10.1002/(ISSN)1552-4833)]

**TABLE I**  
Frequencies of Numerical and Structural Abnormalities From Different Prenatal Clinical Settings

	AMA		AMA/aUS		AMA/aMSS		AMA/FHx		aUS		aMSS		FHx		Total	%	
	AF	CVS	AF	CVS	AF	CVS	AF	CVS	AF	CVS	AF	CVS	AF	CVS			
<b>CVS</b>																	
Normal karyotype	465	194	30	21	148	101	69	19	64	146	62	109	69	20	1517	87.9	
Num. Abn (NA)	23	8	29	7	29	15	3	2	25	15	10	8	2	0	176	10.2	
Trisomy 21	8	5	12	1	14	12	2	2	9	3	5	6	0	0	79	4.6	
Other NA	7	3	15	4	14	2	0	0	16	11	4	1	0	0	77	4.5	
Mosaic NA	8	0	2	2	1	1	1	0	0	1	1	1	2	0	20	1.2	
<b>Struct. Abn (SA)</b>	<b>4</b>	<b>1</b>	<b>0</b>	<b>2</b>	<b>1</b>	<b>1</b>	<b>5</b>	<b>1</b>	<b>2</b>	<b>8</b>	<b>0</b>	<b>3</b>	<b>5</b>	<b>0</b>	<b>33</b>	<b>1.9</b>	
Unb. SA	2 (1) <sup>a</sup>	0	0	1 (1)	0	0	1	0	1	5 (4)	0	1	1	1	0	12	0.7
Bal. SA	2 (1)	1	0	1 (1)	0	0	4	1	1	2	0	1	3 (1)	0	16	0.9	
Mosaic SA	0	0	0	0	1	1 (1)	0	0	0	1	0	1	1 (1)	0	5	0.3	
<b>Total</b>	<b>492</b>	<b>203</b>	<b>59</b>	<b>30</b>	<b>178</b>	<b>117</b>	<b>77</b>	<b>22</b>	<b>91</b>	<b>169</b>	<b>72</b>	<b>120</b>	<b>76</b>	<b>20</b>	<b>1726</b>		
Abn %	5.5	4.4	49.2	30	16.9	13.7	10.4	13.6	29.7	13.6	13.9	9.2	9.2	0			

AMA, advance maternal age; aMSS, abnormal maternal serum screening; aUS, abnormal ultrasound; FHx, family history; Unb, unbalanced; Bal, Balanced.

<sup>a</sup>Number within parenthesis for cases further analyzed by aCGH.

TABLE II

Summary of Prenatal Clinical Features and Abnormalities Detected by G-Band and aCGH

Case no.	Clinical indication	Karyotype/FISH	aCGH findings <sup>a</sup>	Parental study	Follow-up
1 (CV)	AMA	46,XY,del(3)(p25.3)mat	3p26.3p25.3(48,714–9,332,435) × 1	46,XX,del(3)(p25.3)	Normal newborn
2 (AF)	AMA, aMSS	47,XY,+mar[14]/46,XY[6], nuc ish (CEP4×3)[189]/(CEP4×2)[11]	4p13q13.1(44,026,548–62,632,708)×2–3	Normal	Normal development at 1 year
3 (AF)	aUS, FHx	46,XX,der(5)(p14.1;q35)pat.ish der(5)(5:7)(5pter–, 5qter+,7qter–)	5p13.33p14.1(78,942–24,977,357)×1, 7q35q36.3(143,495,352–158,781,538)×3	46,XY,t(5:7)(p141;q35)	Terminated
4 (AF)	aUS, aMSS	46,XX,del(6)(q27)dn.ish(6pter+,6qter–)	6q27(IG5,927,396–170,809,934)×1	Normal	Ventriculomegaly
5 (AF)	AMA, aUS, aMSS	46,XY,rec(8)dup(8p)inv(8)(p12q24.3)pat	8p23.3p21.1(181,530–28,441,283) × 3, 8q243(145,464,363–146,250,824)×1	46,XY,inv(8)(p12q24.3)	Terminated
6 (AF)	aUS, FHx	47,XX,+der(9)(8:9)(p11.21;q13)mat	8p23.3p11.21(181,530–42,866,112)×3, 9p243p13.1(204,367–40,238,102)×3	46,XX,t(8:9)(p11.21;q13)	Multiple abnormalities, died on 2 days
7 (CV)	AMA	46,XX,t(11;14)(q21;q31)dn	Normal	Normal	Normal at birth
8 (CV)	FHx	46,XX,add(12)(q243)[11]/46,XX[9] ish add(12)(q24.3)(82GF19++)[12/15] ish nuc (82GF19×3)[45/50] nuc ish (33M11,696J7)×3[40/50]	4q35.2(184,187,538–190,490,075)×2–3, 5q21.1(99,486,385–100,401,951) × 3–4(100,678,690–103,437,734)×2–3, 12q24.32q33 (125,761,905–132,378,336) ×2–3	N/A	Terminated
9 (AF)	AMA, aUS, FHx	46,XY,der(13)del(13)(q33.1q34)(13;15) (q34;q25), der(15)t(13;15)(q34;q25)dn	13q33.1q34 (100,838,094–114,077,122)×1	Normal	Abnormal newborn (see text)
10 (AF)	aUS	46,XX,der(18)dup(18) (q12.3q22.1)del(18)(q22.1q23)dn	18q12.3q22.1(40,535,628–63,364,951)×3, 18q22.1q23(63,549,666–76,083,117)×1	Normal	Abnormal newborn (see text)
11 (CV)	FHx of der(21)	46,XY,ins(19;21)(q13.1; q21.3q22.13)pat.ish(RUNX1+; RUNX1–,115208+,347BS+)	Normal	46,XY,ins(19;21)(q13.1; q21.3q22.13)	Normal

CV, chorionic villus; AF, amniotic fluid; AMA, advance maternal age; aMSS, abnormal maternal serum screen; aUS, abnormal ultrasound, FHx, family history; N/A, not available.

<sup>a</sup> Agilent 180K on cases 1–3 (NCBI3G/hg18) and 11; and 44K on cases 4–10 (NCBI35/hg17).